

# Heparin-induced thrombosis with a normal platelet count

George F Alvarez, David Bihari and David Collins

Heparin is widely used in critical care medicine for both prevention and treatment of deep vein thrombosis (DVT) and pulmonary embolism. Recent evidence-based guidelines recommend that all critically ill patients should receive some form of DVT prophylaxis, the most common being heparin.<sup>1,2</sup> Side effects of heparin include bleeding and, paradoxically, thrombosis associated with heparin-induced thrombocytopenia (HIT). HIT is an immune-mediated disorder that provokes an extreme prothrombotic state.<sup>3</sup> Of clinical significance, this state can persist for weeks after ceasing heparin.<sup>4,5</sup> The clinical sequelae are venous and arterial thromboemboli which can produce pulmonary embolism, myocardial infarction, stroke, limb loss and even death.<sup>6-10</sup> We describe a patient with a rare presentation of this important problem.

## Clinical record

A previously healthy 30-year-old woman (gravida 2, para 2) presented with a left-sided cerebral vascular accident 2 weeks after giving birth. Both pregnancies had been unremarkable. She presented to a peripheral hospital with confusion, dysarthria, right hemiparesis and a Glasgow Coma Scale score of 15/15. Initial computed tomography (CT) of the head found no abnormality. It was therefore decided to treat her with aspirin, clopidogrel and systemic heparinisation. On transfer to a peripheral stroke unit 6 hours after presentation, the patient suffered recurrent seizures despite repeated boluses of diazepam. Repeat CT of the head showed left frontal intracerebral haemorrhage with oedema and midline shift. Her level of consciousness deteriorated, and she was electively intubated, treated with protamine, phenytoin and mannitol, and transferred to a tertiary referral hospital.

On admission to the intensive care unit (Day 0), CT of the head showed an increase in oedema and midline shift, and a new large infarct with haemorrhage. Later that day, a decompressive craniectomy was performed, and an extra-ventricular drain pressure monitor was inserted. Standard Brain Trauma Foundation ([www.braintrauma.org](http://www.braintrauma.org)) guidelines for raised intracerebral pressure were instituted. Post-operative CT of the head showed a decrease in the midline shift, no increase in haemorrhage, and thrombosis of the superior sagittal sinus. Results of other initial investigations are summarised in Table 1. It was elected to heparinise the patient and to keep the activated partial thromboplastin time (APTT) within the "low" therapeutic range.

## ABSTRACT

Heparin is commonly used in the intensive care unit for preventing and treating thromboembolic disease. One of its more significant complications is heparin-induced thrombocytopenia (HIT), an immune-mediated disorder which can provoke an extreme prothrombotic state. We describe an unusual presentation of HIT, where thrombocytopenia was absent.

Crit Care Resusc 2007; 9: 51-54

Subsequent CT scans of the head during heparin treatment showed continuing reduction in haemorrhage, oedema and mass effect; flow was evident around the thrombosis. On Day 7, the intracerebral pressure monitor was removed, and on Day 8 the patient was successfully extubated. Later that day, her temperature spiked to 38.5°C. Table 2 shows the daily maximum temperature, serum procalcitonin levels and white blood cell count over the ensuing 2 weeks.

Blood cultures on Days 8, 9, 11, 12, 13 and 16 gave negative results. Urine and stool cultures, previous cerebrospinal fluid cultures, tests for *Clostridium difficile* toxin and methicillin-resistant *Staphylococcus aureus* swabs also gave negative results.

The central venous catheter and arterial line were removed on Day 10. On Day 12, broad-spectrum antibiotics were started. On Day 13, repeat CT of the head, sinus, chest, abdomen and pelvis showed no focus of infection but revealed a large thrombus of the right iliofemoral vein extending into the inferior vena cava. Results of investigations on Days 14 and 15 are shown in Table 1.

On Day 15, heparin was ceased because of presumed heparin failure, and lepirudin was started. After 48 hours of heparin cessation, the patient's temperature returned to normal (Table 2). The next day, HIT screening results became available, and were positive for heparin-platelet factor 4 antibodies but negative for heparin-induced serotonin release. Figure 1 compares platelet count and APTT throughout the patient's ICU stay.

The patient was discharged after 21 days in the ICU to a stroke rehabilitation ward. She returned to hospital after 3 months for elective repair of the skull defect/cranioplasty, had an uneventful postoperative course, and was dis-

**Table 1. Investigations in the first 24 hours of admission and on Days 14 and 15**

Investigation	Results
<b>First 24 hours</b>	
Carotid duplex ultrasonography	No significant disease
Electroencephalogram	No seizure activity
Viral serology and hepatitis screen	Negative
Procoagulant and vasculitis screen*	Negative
Transoesophageal echocardiogram	Normal left and right ventricles, and valvular function
Doppler lower limbs†	Small amount of clot in right common femoral vein related to central line cannulas
<b>Days 14 and 15</b>	
Transthoracic echocardiogram	Normal with no demonstrable vegetations
Radiolabelled gallium whole-body survey	No evidence of active infection or gallium-avid tumour
Computed tomography pulmonary angiogram	Widespread pulmonary embolism with infarction in left lung
Doppler upper extremities	Bilateral internal jugular and subclavian vein occlusions

\*This included antithrombin, protein C and protein S levels, lupus anticoagulant, kaolin clotting time, dilute Russell's viper venom time, IgM and IgG anticardiolipin antibodies, factor V Leiden G1691A, prothrombin G20210A and MTHFR C677T mutations, homocysteine level, cryoglobulins, antinuclear and antineutrophil cytoplasmic antibodies, complement components C3 and C4, rheumatoid factor and all extractable nuclear antigens.

† After the result was known, the femoral line was replaced with a subclavian central venous catheter. ♦

charged again when the international normalised ratio returned to the normal range.

**Discussion**

Three distinct patterns of HIT have been described. Classically, HIT is defined as a fall in platelet count >50% (or below 100 × 10<sup>9</sup> cells/L), usually occurring after 5 to 10 days

of heparin exposure.<sup>11,12</sup> Second, in patients with previous heparin exposure, thrombocytopenia can occur within 24 hours.<sup>13,14</sup> Third, delayed onset HIT can occur several days to weeks after heparin is ceased and is typically more severe in terms of thrombogenicity.<sup>15,16</sup> The incidence of HIT is quoted as around 3%–5% for intravenous unfractionated heparin.<sup>17</sup> The incidence is lower with subcutaneous heparin and catheter flushes, but HIT can occur even after exposure to heparin-coated catheters.<sup>18-20</sup>

The main underlying pathophysiology of HIT is the formation of IgG antibodies against a complex formed between heparin and platelet factor 4 (PF4), a positively charged protein from platelet α-granules.<sup>21</sup> This complex then binds to the Fab receptors on platelets, causing platelet activation and aggregation. Subsequent activation of the coagulation pathways and platelet clearance in the reticuloendothelial system are responsible for the thrombosis and thrombocytopenia typical of the full-blown syndrome.<sup>22</sup>

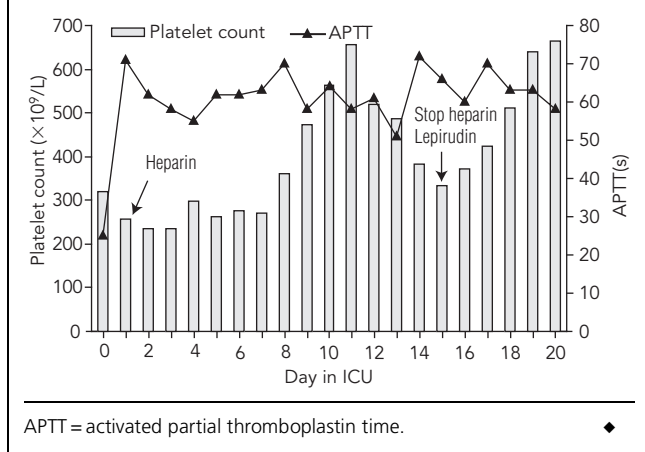
Tests for HIT are either functional (which assess platelet activation or aggregation in the presence of heparin) or immunological (which detect antibody to heparin–PF4).<sup>22</sup> In our hospital, we perform a screening immunological test followed by a “gold standard” functional test. The screening test assesses heparin-dependent antibodies to platelet factor 4 and has reasonable sensitivity and specificity (both 85%).<sup>23</sup> The gold standard is the serotonin-release assay (SRA), which uses donor platelets tagged with radiolabelled serotonin. These are washed in patient plasma and exposed to heparin at varying concentrations.<sup>24-26</sup> Serotonin release at low versus high heparin concentrations has good sensitivity (90%–98%) and specificity (80%–95%) for HIT. Our patient was one of the few with HIT to have a false-negative SRA result, although the screening test was positive.

HIT is usually associated with a fall in platelet count, but our patient's platelet count actually increased (Figure 1). Furthermore, pulmonary embolism is also associated with a low platelet count.<sup>27,28</sup> In our patient, could the reactive thrombocytosis from systemic inflammatory response syndrome have masked the expected drop in platelet count?<sup>29</sup> We have found only one specific mention in the literature of secondary thrombocytosis and its impact on HIT diagnosis.<sup>30</sup> One group has published on normal platelet counts and HIT; the original case report<sup>31</sup> was followed by

**Table 2. Serial white cell counts, procalcitonin levels and daily maximum temperature**

	Day in intensive care unit											
	7	8	9	10	11	12	13	14	15	16	18	20
White cell count (× 10 <sup>9</sup> cells/L)	6.8	8.3	9.5	8.8	11.0	8.6		16.3	11.2	10.7	9.3	9.5
Serum procalcitonin level (ng/mL)	–	0.2	0.1	–	<0.1	0.4	0.5	0.5	–	0.6	0.1	–
Daily maximum temperature (°C)	37.5	38.5	38.5	39.0	39.3	39.9	40.1	40.2	39.8	38.8	37.8	37.2

**Figure 1. Therapeutic heparinisation and platelet counts during intensive care unit stay**



a case series of 10 patients who all experienced thrombotic occlusion of vascular grafts related to surgery.<sup>32</sup> Of note, half the patients had intraoperative graft occlusion, but there was no mention of anatomic or haemodynamic parameters that may have otherwise explained the thrombosis. In fact, only one patient is reported to have had a DVT (ie, an occlusive episode outside the graft or adjacent arteries).

Our patient exemplifies HIT without accompanying thrombocytopenia. The diagnosis was not considered early in the course of illness because of a single normal laboratory result (platelet count), despite other clues. Furthermore, the patient was one of the few with HIT to have a false-negative SRA result. Clinicians should be aware that HIT can present without thrombocytopenia and with negative results on a gold standard test.

**Author details**

George F Alvarez, Intensivist<sup>1</sup>

David Bihari, Intensivist<sup>2</sup>

David Collins Intensivist,<sup>2</sup>

1 Department of Critical Care, Rockyview General Hospital, Calgary, Alberta, Canada.

2 Intensive Care Unit, Prince of Wales Hospital, Sydney, NSW.

Correspondence: George.Alvarez@calgaryhealthregion.ca

**References**

1 Buller HR, Agnelli G, Hull RD, et al. Antithrombotic therapy for venous thromboembolic disease: the Seventh ACCP Conference on Antithrombotic and Thrombolytic Therapy. *Chest* 2004; 126 (3 Suppl): 401S-285.

2 Rogers FB, Cipolle MD, Velmahos G, et al. Practice management guidelines for the prevention of venous thromboembolism in

trauma patients: the EAST practice management guidelines work group. *J Trauma* 2002; 53: 142-64.

3 Warkentin TE, Kelton JG. Heparin-induced thrombocytopenia. *Annu Rev Med* 1989; 40: 31-44.

4 Warkentin TE, Kelton JG. A 14-year study of heparin-induced thrombocytopenia. *Am J Med* 1996; 101: 502-7.

5 Wallis DE, Workman DL, Lewis BE, et al. Failure of early heparin cessation as treatment for heparin-induced thrombocytopenia. *Am J Med* 1999; 106: 629-35.

6 Kapsch D, Silver D. Heparin-induced thrombocytopenia with thrombosis and hemorrhage. *Arch Surg* 1981; 116: 1423-7.

7 Kapsch DN, Adelstein EH, Rhodes GR, Silver D. Heparin-induced thrombocytopenia, thrombosis, and hemorrhage. *Surgery* 1979; 86: 148-55.

8 Cimo PL, Moake JL, Weinger RS, et al. Heparin-induced thrombocytopenia: association with a platelet aggregating factor and arterial thromboses. *Am J Hematol* 1979; 6: 125-33.

9 Rhodes GR, Dixon RH, Silver D. Heparin induced thrombocytopenia: eight cases with thrombotic-hemorrhagic complications. *Ann Surg* 1977; 186: 752-8.

10 King DJ, Kelton JG. Heparin-associated thrombocytopenia. *Ann Intern Med* 1984; 100: 535-40.

11 Lubenow N. New developments in diagnosis and treatment of heparin-induced thrombocytopenia. *Pathophysiol Haemost Thromb* 2003; 33: 407-12.

12 Warkentin TE, Chong BH, Greinacher A. Heparin-induced thrombocytopenia: towards consensus. *Thromb Haemost* 1998; 79: 1-7.

13 Lubenow N, Kempf R, Eichner A, et al. Heparin-induced thrombocytopenia: temporal pattern of thrombocytopenia in relation to initial use or reexposure to heparin. *Chest* 2002; 122: 37-42.

14 Warkentin TE, Kelton JG. Temporal aspects of heparin-induced thrombocytopenia. *N Engl J Med* 2001; 344: 1286-92.

15 Rice L, Attisha WK, Drexler A, Francis JL. Delayed-onset heparin-induced thrombocytopenia. *Ann Intern Med* 2002; 136: 210-5.

16 Warkentin TE, Kelton JG. Delayed-onset heparin-induced thrombocytopenia and thrombosis. *Ann Intern Med* 2001; 135: 502-6.

17 Warkentin TE. Heparin-induced thrombocytopenia. 3rd ed. New York: Marcel Dekker, 2004.

18 Girolami B, Prandoni P, Stefani PM, et al. The incidence of heparin-induced thrombocytopenia in hospitalized medical patients treated with subcutaneous unfractionated heparin: a prospective cohort study. *Blood* 2003; 101: 2955-9.

19 Warkentin TE, Levine MN, Hirsh J, et al. Heparin-induced thrombocytopenia in patients treated with low-molecular-weight heparin or unfractionated heparin. *N Engl J Med* 1995; 332: 1330-5.

20 Laster J, Silver D. Heparin-coated catheters and heparin-induced thrombocytopenia. *J Vasc Surg* 1988; 7: 667-72.

21 Amiral J, Bridey F, Dreyfus M, et al. Platelet factor 4 complexed to heparin is the target for antibodies generated in heparin-induced thrombocytopenia. *Thromb Haemost* 1992; 68: 95-6.

22 Chong BH. Heparin-induced thrombocytopenia. *J Thromb Haemost* 2003; 1: 1471-8.

23 Warkentin TE, Greinacher A. Heparin-induced thrombocytopenia: recognition, treatment, and prevention: the Seventh ACCP Conference on Antithrombotic and Thrombolytic Therapy. *Chest* 2004; 126 (3 Suppl): 311S-375.

24 Kelton JG, Sheridan D, Santos A, et al. Heparin-induced thrombocytopenia: laboratory studies. *Blood* 1988; 72: 925-30.

25 Izbán KF, Lietz HW, Hoppensteadt DA, et al. Comparison of two PF4/heparin ELISA assays for the laboratory diagnosis of heparin-induced thrombocytopenia. *Semin Thromb Hemost* 1999; 25 Suppl 1: 51-6.

## CASE REPORTS

- 26 Sheridan D, Carter C, Kelton JG. A diagnostic test for heparin-induced thrombocytopenia. *Blood* 1986; 67: 27-30.
- 27 Mustafa MH, Mispireta LA, Pierce LE. Occult pulmonary embolism presenting with thrombocytopenia and elevated fibrin split products. *Am J Med* 1989; 86: 490-1.
- 28 Monreal M, Lafoz E, Casals A, et al. Platelet count and venous thromboembolism. A useful test for suspected pulmonary embolism. *Chest* 1991; 100: 1493-6.
- 29 Schafer AI. Thrombocytosis. *N Engl J Med* 2004; 350: 1211-9.
- 30 Warkentin TE, Roberts RS, Hirsh J, Kelton JG. An improved definition of immune heparin-induced thrombocytopenia in post-operative orthopedic patients. *Arch Intern Med* 2003; 163: 2518-24.
- 31 Hach-Wunderle V, Kainer K, Krug B, et al. Heparin-associated thrombosis despite normal platelet counts. *Lancet* 1994; 344: 469-70.
- 32 Hach-Wunderle V, Kainer K, Salzmann G, et al. Heparin-related thrombosis despite normal platelet counts in vascular surgery. *Am J Surg* 1997; 173: 117-9. □