

# Independent lung ventilation in the intensive care unit: desperate measure or viable treatment option?

Kiran Shekar, Carole L Foot and John F Fraser

## Clinical records

### Patient 1

A 69-year-old man, with a 40-pack-year history of smoking and known chronic obstructive pulmonary disease, presented to his local hospital with chest pain and dyspnoea. A chest radiograph showed right-sided pneumothorax following rupture of a large apical emphysematous bulla. This was decompressed by insertion of two intercostal catheters. However, he had a massive air leak associated with increasing subcutaneous emphysema, which necessitated transfer to our centre for surgical correction of the air leak (Figure 1A).

Following induction of anaesthesia, a left-sided 39 Fr double-lumen tube (Sims Portex, Keene, NH, USA) was inserted, and video-assisted thoracoscopy and partial right upper lobectomy were performed, with excision of the bulla. BioGlue (CryoLife International, Kennesaw, GA, USA; 10 mL) was also applied. The patient was returned to the intensive care unit intubated, where he was initially ventilated conventionally with synchronised intermittent manda-

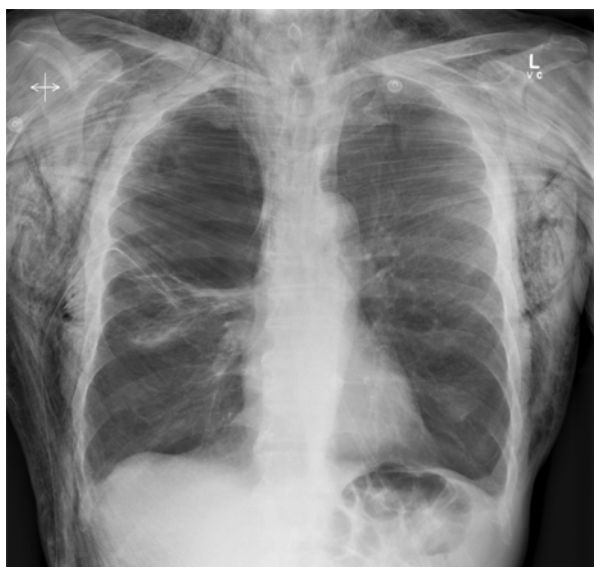## ABSTRACT

Independent lung ventilation is often used intra-operatively but has also been used in intensive care in a variety of clinical situations. Ventilating lungs independently of each other may be life-saving when a lung abnormality is predominantly unilateral. We successfully used independent lung ventilation in two patients, who benefited from anatomical and physiological separation of their lungs. These cases remind intensivists that independent lung ventilation is a viable option to be considered in cases of pulmonary abnormality when conventional mechanical ventilation is deleterious.

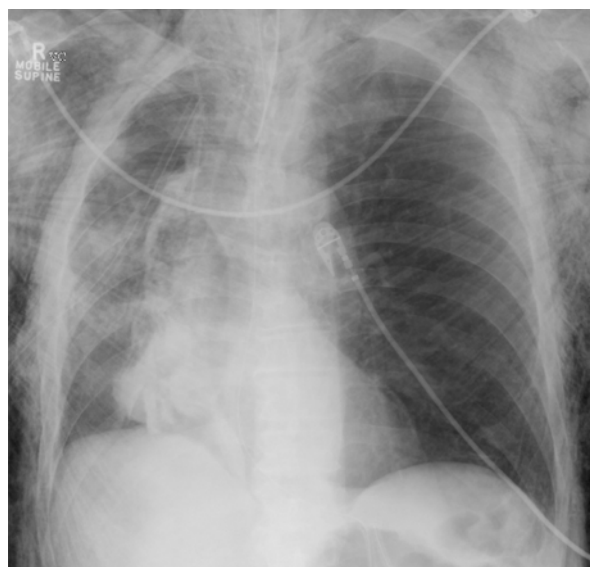Crit Care Resusc 2008; 10: 144–148

tory ventilation (SIMV) volume control due to the difficult airway (Cormack and Lehane Grade 3) and extensive subcutaneous emphysema.

**Figure 1. Serial chest x-rays in Patient 1**



**A.** After initial decompression of a right-sided pneumothorax, x-ray showed bilateral bullous emphysema, a large right apical bulla and extensive subcutaneous emphysema.



**B.** Chest x-ray after attempted surgical correction of the air leak, showing collapse of the right lung with opacification of the right apical region from BioGlue, a right-sided chest drain, gross hyperinflation of the left side and extensive subcutaneous emphysema.

**Table 1. Patient 1 initial ventilator settings and arterial blood gas results after institution of independent lung ventilation**

Parameter	Right lung	Left lung
<b>Ventilator settings</b>		
Mode of ventilation	PCV	PCV
FiO <sub>2</sub>	0.8	0.8
PEEP (cmH <sub>2</sub> O)	0	5
Peak inspiration pressure (cmH <sub>2</sub> O)	32	23
Tidal volume (mL)	100	300
Respiratory rate (breaths per min)	12	20
I : E ratio	1 : 6.2	1 : 3.5
Peak airway pressure (cmH <sub>2</sub> O)	32	25
<b>Blood gas results (RR)*</b>		
pH	7.46 (7.35 to 7.45)	
PaCO <sub>2</sub> (mmHg)	34.3 (35 to 45)	
PaO <sub>2</sub> (mmHg)	391 (75 to 100)	
SaO <sub>2</sub> (%)	100% (94% to 98%)	
HCO <sub>3</sub> (mmol/L)	22.3 (22 to 33)	
Base excess (mmol/L)	-0.9 (-3.0 to 3.0)	

PCV = pressure controlled ventilation.

PEEP = positive end-expiratory pressure.

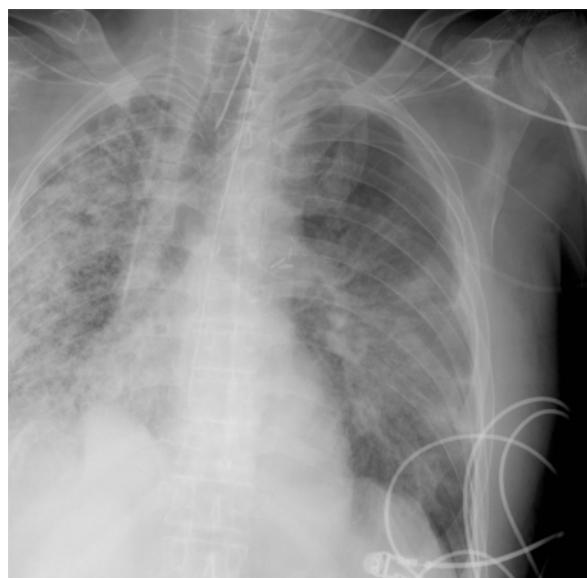
I : E = inspiratory : expiratory time. RR = reference range.

\* No blood gas samples were taken before independent lung ventilation was instituted, because of critical worsening hypoxia, demonstrated on pulse oximetry.

In the ICU, the air leak persisted despite strategies to minimise mean airway pressure, including low tidal volume, zero positive end-expiratory pressure (PEEP) and attempts at spontaneous breathing. A postoperative chest x-ray showed a collapsed right lung. As this was associated with rapidly worsening oxygenation, respiratory acidosis and an ongoing large air leak (Figure 1B), it was decided to reinstitute independent lung ventilation.

A left-sided 39 Fr double-lumen tube was placed and, after effective lung separation was confirmed, asynchronous independent lung ventilation was instituted with two ventilators (Puritan Bennett 840, Puritan Bennett Corporation, USA). Positive end-expiratory pressure and mean airway pressure were minimised on the affected lung, which reduced the air leak, leading to closure of the fistula over 48 hours. The parameters for ventilation of the left lung, which was also emphysematous, were optimised for oxygenation and ventilatory needs while minimising the risk of barotrauma (see Table 1 for the ventilator settings and associated arterial blood gas parameters). When ventilation was adequately established, bronchoscopy was performed through the double-lumen tube, allowing removal of copious bloody material from the right main bronchus, facilitat-

**Figure 2. Chest x-ray in Patient 2**



*Chest x-ray on Day 94 after left-lung transplantation, showing fibrosis of the right lung, with evidence of alveolar consolidation of the native and the transplanted left lung.*

ing re-expansion and improved compliance of the right lung. Sedation and neuromuscular paralysis were maintained during this time with propofol, fentanyl and vecuronium infusions.

We replaced the double-lumen tube with a single-lumen endotracheal tube after 24 hours, as the respective lung compliances equalised. The patient was successfully extubated on the third postoperative day and was discharged home on Day 16.

### Patient 2

A 40-year-old man underwent left-sided single-lung transplantation for advanced usual interstitial pneumonitis. His immediate postoperative course was unremarkable, and he was discharged home soon afterwards. On Day 94 postoperatively, he developed progressive respiratory distress associated with an acute haemorrhage in the native lung and soiling of the transplanted lung (Figure 2). The bleeding was attributed to a combination of coagulopathy secondary to haemolytic uraemic syndrome/thrombotic thrombocytopenic purpura (HUS/TTP)-like syndrome (probably triggered by immunosuppression with everolimus) and invasive aspergillosis.

The patient was intubated and ventilated with SIMV volume control after an unsuccessful trial of non-invasive ventilation. Cessation of everolimus, initiation of antifungal therapy (caspofungin and voriconazole), plasma exchange,

**Table 2. Patient 2 ventilator settings and arterial blood gas results before and after initiation of independent lung ventilation**

Parameter	Standard ventilation	Independent ventilation	
		Right lung	Left lung
<b>Ventilator settings</b>			
Mode of ventilation	PCV	PCV	VCV
F <sub>IO<sub>2</sub></sub>	1.0	1.0	0.8
PEEP (cmH <sub>2</sub> O)	14	10	15
Peak inspiration pressure (cmH <sub>2</sub> O)	33	31	–
Tidal volume (mL)	500	130	350
Respiratory rate (breaths per min)	22	16	28
I : E ratio	1 : 1.6	1 : 1.5	1 : 1.5
Peak airway pressure (cmH <sub>2</sub> O)	45	42	30
<b>Blood gas results</b>			
pH	7.35	7.39	
PaCO <sub>2</sub> (mmHg)	53.3	49	
PaO <sub>2</sub> (mmHg)	70.9	78	
SaO <sub>2</sub> (%)	94.8%	97%	
HCO <sub>3</sub> (mmol/L)	28.6	28	
Base excess (mmol/L)	3.3	1.3	

PCV = pressure controlled ventilation. VCV = volume controlled ventilation. PEEP = positive end-expiratory pressure. I : E = inspiratory : expiratory time.

pulse corticosteroid therapy and correction of coagulopathy (with fresh frozen plasma, cryoprecipitate and recombinant coagulation factor VIIa [eptacog alfa]) failed to stop the ongoing bleeding. Attempts at embolisation of the bleeding bronchial artery were aborted when an abnormal communication with the right vertebral artery was detected. With progressive soiling of the transplanted lung and worsening oxygenation, lung separation was achieved with a right-sided double-lumen tube, and the lungs were differentially ventilated. The ventilator settings and arterial blood gas parameters just before beginning independent lung ventilation and the initial settings for independent lung ventilation are shown in Table 2.

With effective anatomical lung separation and ventilator strategies tailored for each lung, the compliance of the transplanted lung improved demonstrably over 2 days. Bronchoscopic examination was performed every 6 hours for the first 24 hours, to confirm the position of the double-lumen tube and for airway toilet. Inhaled nitric oxide (20 ppm) was administered to the transplanted lung during the initial period of severe hypoxaemia. Increased concen-

trations of inspired oxygen to the native lung achieved minimal improvement in systemic oxygenation (evidenced by a rise in the Pao<sub>2</sub> of less than 10 mmHg with F<sub>IO<sub>2</sub></sub> of 0.21–1.0), confirming minimal gas transfer function of the diseased lung. Subsequent bronchoscopy revealed ongoing bleeding of the native lung.

A right-sided pneumonectomy was performed 3 days after the institution of independent lung ventilation. The patient was successfully weaned from mechanical ventilation over the subsequent 2 days. After extensive physical rehabilitation for critical illness weakness, he was discharged home and continued to have good graft function 11 months after discharge.

### Discussion

These cases are a reminder that independent lung ventilation may be a successful treatment when pulmonary disease is markedly asymmetrical or when the pathological process in one lung adversely affects the other. With increasing emphasis on regional and lung-protective ventilation, the price paid to achieve global goals of oxygenation and ventilation is becoming increasingly apparent. Research on various models of lung injury and data from various imaging techniques, such as dynamic computed tomography and electrical impedance tomography, have demonstrated the heterogeneity of both lung injury and the distribution of alveolar ventilation.<sup>1-8</sup> An important limiting factor in conventional ventilation appears to be the non-homogenous distribution of ventilation and PEEP, resulting in secondary lung injuries.<sup>5,9,10</sup> This limitation may be more obvious when abnormalities are complex and unilateral (eg, bronchopleural fistula and unilateral lung contusion), and conventional ventilation fails to achieve the ultimate goal of protecting the lungs while still maintaining satisfactory gas exchange.

Independent lung ventilation has for several years been a therapeutic option for such individuals. However, it has significant limitations. Potential complications — the risk of which increases with duration of therapy — include relative inability to toilet the airway, double-lumen tube blockage, dislodgement and airway trauma.<sup>11-14</sup> The use of independent lung ventilation in patients with severe bilateral lung injury and failure of conventional ventilation remains controversial. Our two cases place these relative risks into perspective. They highlight that, with optimal airway management and intensive care, independent lung ventilation may be efficacious and safe, and ensure adequate oxygenation when all conventional ventilatory modalities have failed, allowing time to resuscitate before definitive management. Common indications for independent lung ventilation are summarised in Table 3.

**Table 3. Indications for independent lung ventilation**<sup>14-21</sup>

**Anatomical**

Unilateral pulmonary haemorrhage  
Severe unilateral pneumonia  
Whole-lung lavage for pulmonary alveolar proteinosis

**Physiological**

Bronchopleural fistula  
Massive unilateral pulmonary embolism  
Single-lung transplantation  
Unilateral pulmonary contusion  
Unilateral bronchospasm

Regardless of the indication, initiation of independent lung ventilation requires lung separation, which is commonly achieved using a double-lumen tube. Alternative methods of lung separation include deliberate blind endobronchial intubation, selective directed endobronchial intubation, selective endobronchial blockade using bronchial blockers,<sup>22</sup> coaxial tubes and the Univent bronchial-blocker tube (Fuji Systems, Tokyo, Japan).<sup>23</sup> Some of these techniques allow only one of the lungs to be ventilated, which may actually worsen hypoxaemia and intrapulmonary shunt, while necessitating lateral positioning of the patient. These techniques have limited relevance outside the operating theatre.

When lung separation is achieved, the choice of ventilatory strategy depends predominantly on the compliance of each lung and the preferences of the intensivist. Asynchronous independent lung ventilation requires two ventilators but is relatively straightforward to establish.<sup>14,24-26</sup> Synchronised ventilation has been reported using two ventilators and a synchronisation cable,<sup>27,28</sup> and alternatively with a single ventilator and a specially designed valve.<sup>17</sup> However, asynchronous ventilation appears to be well tolerated, with haemodynamic instability attributable to asynchrony alone being uncommon.<sup>16</sup> Our cases demonstrate how independent lung ventilation enables ventilation to be tailored to individual lung requirements.

Measurements of end-tidal CO<sub>2</sub> from each lung may help monitor the degree of ventilation/perfusion mismatch and guide ventilatory management.<sup>18</sup> In our Patient 1, with bronchopleural fistula, independent lung ventilation minimised the air leak, facilitating closure of the fistula without compromising ventilatory demands or causing iatrogenic injury to the intact, emphysematous lung. Our Patient 2 demonstrated the integration of anatomical and physiological separation. Placement of a double-lumen tube not only protected the transplanted lung from ongoing soiling, but also allowed each lung to be selectively ventilated, minimising the risk of further lung injury.

We accept that alternative therapies (such as high frequency ventilation and extracorporeal membrane oxygenation [ECMO]) might have been successful in managing our patients without independent lung ventilation, and emphasise that this latter is one way to successfully treat such patients. However, ECMO carries substantial risks and costs, and requires a specialised team, whereas most ICUs can cope with two ventilators at the bedside, maybe requiring an extra nurse and more frequent senior medical attendance only. Our case reports are also not intended as a platform for comprehensive reviews of the management of complications of bronchopleural fistula, pulmonary haemorrhage and lung transplantation, which have been reviewed elsewhere.<sup>29-31</sup>

The lack of evidence from controlled trials and the practicalities of independent lung ventilation may make it a difficult choice even when it may be of benefit. Given the rarity of its use, it is unlikely that it will be subject to a well-designed randomised study. Intensivists must therefore rely on careful case selection, anecdotal evidence and surrogate evidence emerging from various models of lung injury. We hope that our reported cases add to this body of knowledge. Practical information that may be of benefit to intensivists with minimal experience of independent lung ventilation is summarised in Table 4.

Intensivists should familiarise themselves with the technique of double-lumen tube insertion and institution of independent lung ventilation and should consider this a viable therapeutic intervention for selected patients.

**Table 4. Practicalities of independent lung ventilation in the intensive care unit**

- Initiating independent lung ventilation is a challenge, and the problems in maintaining lung separation over long periods should not be underestimated.
- A sufficiently long and thin fibre-optic bronchoscope that fits both lumens of a double-lumen tracheal tube should be available at the bedside at all times.
- Difficulties in suctioning through narrow lumens of a double-lumen tube should be anticipated — non-standard extra-long catheters are required.
- Optimal humidification may help prevent tube blockage.
- Airway trauma related to the double-lumen tube should be expected to increase over time.
- Patient sedation and paralysis are recommended.
- Asynchronous independent lung ventilation with two ventilators works well.
- Independent lung ventilation is an adjunct, not a cure —recovery may not be realistic, but the technique may be worth trialling if no alternatives are available.
- Resources are an issue: extra nurses and increased availability of senior medical staff may be needed.

**Author details**

Kiran Shekar, Intensive Care Registrar  
 Carole L Foot, Intensive Care Specialist  
 John F Fraser, Associate Professor and Director of Critical Care Research Group  
 Critical Care Research Group, Prince Charles Hospital, Brisbane, QLD.  
**Correspondence:** shekarkiran@yahoo.com

**References**

- 1 Meier T, Luepschen H, Karsten J, et al. Assessment of regional lung recruitment and derecruitment during a PEEP trial based on electrical impedance tomography. *Intensive Care Med* 2008; 34: 543-50.
- 2 Rouby JJ, Puybasset L, Nieszkowska A, Lu Q. Acute respiratory distress syndrome: lessons from computed tomography of the whole lung. *Crit Care Med* 2003; 31 (4 Suppl): S285-95.
- 3 Nieszkowska A, Lu Q, Vieira S, et al. Incidence and regional distribution of lung over inflation during mechanical ventilation with positive end-expiratory pressure. *Crit Care Med* 2004; 32: 1496-1503.
- 4 Gattinoni L, Pesenti A, Bombino M, et al. Relationships between lung computed tomographic density, gas exchange, and PEEP in acute respiratory failure. *Anesthesiology* 1988; 69: 824-32.
- 5 Dreyfuss D, Saumon G. Ventilator-induced lung injury: lessons from experimental studies. *Am J Respir Crit Care Med* 1998; 157: 294-323.
- 6 Victorino JA, Borges JB, Okamoto VN, et al. Imbalances in regional lung ventilation: a validation study on electrical impedance tomography. *Am J Respir Crit Care Med* 2004; 169: 791-800.
- 7 Puybasset L, Gusman P, Muller JC, et al. Regional distribution of gas and tissue in acute respiratory distress syndrome. III. Consequences for the effects of positive end-expiratory pressure. CT Scan ARDS Study Group. *Adult Respiratory Distress Syndrome. Intensive Care Med* 2000; 26: 1215-27.
- 8 Puybasset L, Cluzel P, Chao N, et al. A computed tomography scan assessment of regional lung volume in acute lung injury. The CT Scan ARDS Study Group. *Am J Respir Crit Care Med* 1998; 158: 1644-55.
- 9 Vieillard-Baron A, Prin S, Schmitt JM, et al. Pressure-volume curves in acute respiratory distress syndrome: clinical demonstration of the influence of expiratory flow limitation on the initial slope. *Am J Respir Crit Care Med* 2002; 165: 1107-12.
- 10 Dreyfuss D, Martin-Lefèvre L, Saumon G. Hyperinflation-induced lung injury during alveolar flooding in rats: effect of perfluorocarbon instillation. *Am J Respir Crit Care Med* 1999; 159: 1752-7.
- 11 Hurford WE, Alfille PH, Ballin MT, et al. Placement and complications of double-lumen endobronchial tubes. *Anesth Analg* 1992; 74: S141.
- 12 Heiser M, Steinberg JJ, MacVaugh H 3rd, Klineberg PL. Bronchial rupture, a complication of use of the Robertshaw double-lumen tube. *Anesthesiology* 1979; 51: 88.
- 13 Van Dyck MJ, Astiz I. Kinking of a right-sided double lumen tube in the right upper lobe bronchus. *Anesthesiology* 1994; 80: 1410-1.
- 14 Anatham D, Jagadesan R, Tiew PEC. Clinical review: independent lung ventilation in critical care. *Crit Care* 2005; 9: 594-600.
- 15 Claypool WD, Rogers RM, Matuschak, GM. Update on the clinical diagnosis, management, and pathogenesis of pulmonary alveolar proteinosis (phospholipidosis). *Chest* 1984; 85: 550-8.
- 16 Ost D, Corbridge T. Independent lung ventilation. *Clin Chest Med* 1996; 17: 591-601.
- 17 Carvalho P, Thompson WH, Riggs R, et al. Management of bronchopleural fistula with a variable-resistance valve and a single ventilator. *Chest* 1997; 111: 1452-4.
- 18 Cinnella G, Dambrosio M, Brienza N, et al. Independent lung ventilation in patients with unilateral pulmonary contusion. Monitoring with compliance and EtCO(2). *Intensive Care Med* 2001; 27: 1860-7.
- 19 Baumann MH, Sahn SA. Medical management and therapy of bronchopleural fistulas in the mechanically ventilated patient. *Chest* 1990; 97: 721-8.
- 20 Gavazzeni V, Iapichino G, Mascheroni D, et al. Prolonged independent lung respiratory treatment after single lung transplantation in pulmonary emphysema. *Chest* 1993; 103: 96-100.
- 21 David LD, Lee KB, Douglas WM. A 47-year-old woman with wheezing and respiratory failure unresponsive to conventional ventilatory modalities. *Chest* 2002; 121: 1688-91.
- 22 Doyle DJ. Bronchial blockade to improve alveolar ventilation. *Can J Anesth* 1993; 40: 1223-4.
- 23 Inoue H, Shohtsu A, Ogawa J, et al. New device for one-lung anesthesia: endotracheal tube with movable blocker. *J Thorac Cardiovasc Surg* 1982; 83: 940-1.
- 24 Hillman K, Barber J. Asynchronous independent lung ventilation (AILV). *Crit Care Med* 1980; 8: 390-5.
- 25 Mortimer AJ, Laurie PS, Garrett H, Kerr JH. Unilateral high frequency jet ventilation. Reduction of leak in bronchopleural fistula. *Intensive Care Med* 1984; 10: 39-41.
- 26 Dodds CP, Hillman KM. Management of massive air leak with asynchronous independent lung ventilation. *Intensive Care Med* 1982; 8: 287-90.
- 27 Marraro G, Marinari M, Rataggi M. The clinical application of synchronized independent lung ventilation (SILV) in pulmonary disease with unilateral prevalence in pediatrics. *Int J Clin Monit Comput* 1987; 4: 123-9.
- 28 Watts DC, Boustany CB, Lund N, et al. Pressure-controlled inverse ratio synchronized independent lung ventilation for a blast wound to the chest. *Clin Intensive Care* 1991; 2: 356-8.
- 29 Lois M, Noppen M. Bronchopleural fistulas: an overview of the problem with special focus on endoscopic management. *Chest* 2005; 128: 3955-65.
- 30 Winter, SM, Ingbar DH. Massive hemoptysis: pathogenesis and management. *J Intensive Care Med* 1988; 3: 171-88.
- 31 Burton CM, Milman N, Carlsen J, et al. The Copenhagen National Lung Transplant Group: survival after single lung, double lung, and heart-lung transplantation. *J Heart Lung Transplant* 2005; 24: 1834-43. □