

# The Imaginary Line Method is Not Reliable For Identification of Prosthetic Heart Valves on AP Chest Radiographs

C. L. FOOT\*, J. COUCHER†, M. STICKLEY‡, J. MUNDY§, B. VENKATESH\*

\*Department of Intensive Care, Princess Alexandra Hospital, University of Queensland, QUEENSLAND

†Department of Radiology, Princess Alexandra Hospital, QUEENSLAND

‡Department of Emergency Medicine, Princess Alexandra Hospital, QUEENSLAND

§Department of Cardiac Surgery, Princess Alexandra Hospital, QUEENSLAND

---

## ABSTRACT

**Objective:** To examine the utility of four criteria for distinguishing aortic from mitral valve prostheses on supine anteroposterior (AP) chest x rays in critically ill patients.

**Materials and methods:** Two reviewers independently examined the post operative chest X-rays (CXR) of all patients undergoing either an aortic or mitral valve replacement over a 32 month period, in a blinded fashion. They applied four criteria to each film. For each criterion a sensitivity and specificity of differentiating the valve positions correctly was calculated for each reviewer, as well as a kappa statistic for inter-observer agreement between the two reviewers.

**Results:** Two hundred and twenty seven CXR's were evaluated by each of the reviewers. There were 174 aortic and 53 mitral valve replacements. There was a high level of inter-observer agreement for all four criteria applied (kappa values 0.785 to 0.966). Criterion one (imaginary line method) could be applied by both reviewers to less than 50% of CXR's, and when applied was specific but not sensitive. The other three criteria could be applied by both reviewers to approximately 80% of films. Criterion 2 (orientation method) was sensitive but not specific. Criteria 3 (valve orifice method) and 4 (perceived direction of blood flow method) were both highly sensitive and specific and are therefore the best methods.

**Conclusions:** The well known imaginary line method is of limited value when identifying prosthetic valve positions on supine AP CXR's. We advocate the use of the "valve orifice" method or the "perceived direction of blood flow" method to gain valuable information regarding the presence and position of prosthetic heart valves. (**Critical Care and Resuscitation 2006; 8: 15-18**)

**Key words:** Prostheses, heart valve, anteroposterior radiograph

---

Identification of a prosthetic heart valve may have important implications for patient care in the setting of critical illness. For example, aortic valves are generally more susceptible to infective endocarditis and mitral valves to thrombotic complications.

Several reference articles describing the radiographic appearance of specific valves in past and present usage are available.<sup>1-3</sup> However, there is a paucity of recent literature regarding reliable methods to determine the precise location of valve prostheses on a

radiograph.<sup>4-6</sup>

Whilst the use of a radiograph to determine the location of a valve might be considered to be of historical interest only and has been largely supplanted by echocardiography, this issue is still of importance in situations where access to an echocardiography is not available (such as in peripheral hospitals and during out of hours in certain hospitals and in a majority of hospitals in third world countries). X-rays containing radio opaque prosthetic valves also may be encountered

---

Correspondence to: Dr. C. Foot, Intensive Care Unit, Prince Charles Hospital, Queensland 4102  
(e-mail: carole\_foot@yahoo.com.au)

in the examinations where candidates are expected to comment on the devices present.

The most commonly-employed method for postero-anterior (PA) chest radiographs (CXR) is the use of an imaginary line passing from the right cardio-phrenic angle to the inferior aspect of the left hilum. The aortic valve should lie above, and the mitral valve below this line. Other methods include valve orientation (vertical, oblique or horizontal), valve orifice appearance (en face, in profile or in between) and perceived direction of blood flow across the valve (toward the cardiac apex or ascending aorta). These rules have been derived based on PA chest radiographs. It is well known that in anteroposterior (AP) CXR, mediastinal and cardiac silhouettes are distorted and the applicability of these rules is called into question.

Only one study by Gross *et al* tested the validity of these rules in anteroposterior (AP) CXR's in 77 post-operative cardiac surgical patients undergoing mitral and/or aortic valve replacements. They concluded that direction of flow was the best criterion, orifice and orientation were considerably less useful, and the imaginary line method was completely unreliable, due to variability in patient position and beam angle obtained using mobile units.<sup>6</sup> Of note, however, almost ninety percent of patients in this series had a Bjork-Shiley monocuspid disc valve, which is no longer implanted. The remaining valves were Starr-Edwards or porcine valves.

The changing trends in valve surgery over the last 20 years (increasing use of bioprostheses, trend away from Bjork-Shiley and increasing use of mitral valve repair) and radiology (the implementation of digital radiography) call for a need to re-examine the question of valve identification on CXR. Consequently we set out to assess these criteria for determining valve position using a large contemporary cohort of post cardiac surgical patients.

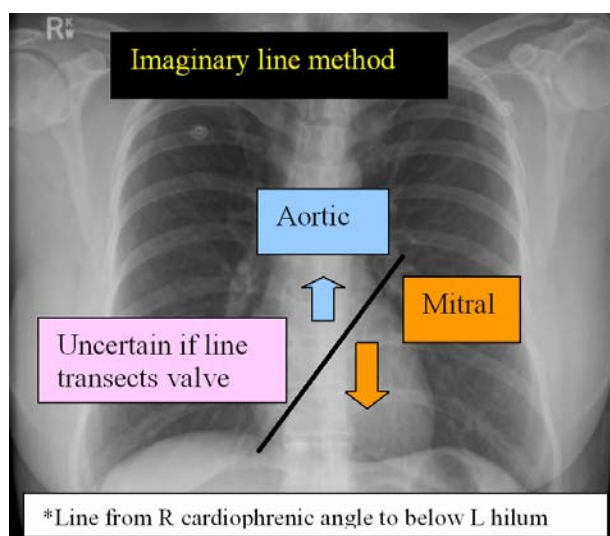
**MATERIALS AND METHODS**

All patients undergoing a single valve replacement (aortic or mitral only) at our institution between 1.11.2000 (the time when the radiology department commenced using digital imaging exclusively) to 31.7.2003 (the time of commencement of the study) were identified retrospectively from the hospitals cardiac surgical database. During this period radio opaque valves implanted included bileaflet disc valves (St Jude, ATS) and bioprosthetic valves (Medtronic mosaic, Baxter perimount). Patients having mitral valve repairs or insertion of a homograft were excluded because the materials utilised are radiolucent. Permission to review the medical notes and digital

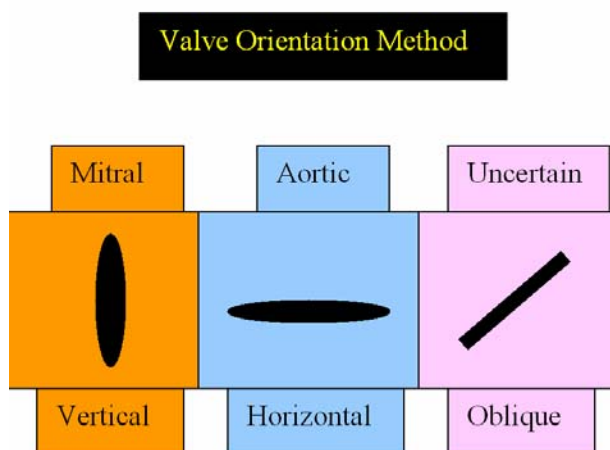
CXR's was obtained from the Hospital's Ethics Committee before commencing the study.

For each patient, the best quality post-operative supine AP CXR performed within the first twenty four hours post-operatively was reviewed independently by two of the authors (an intensive care senior registrar (CF) and qualified radiologist (JC)), blinded to the type of surgery performed.

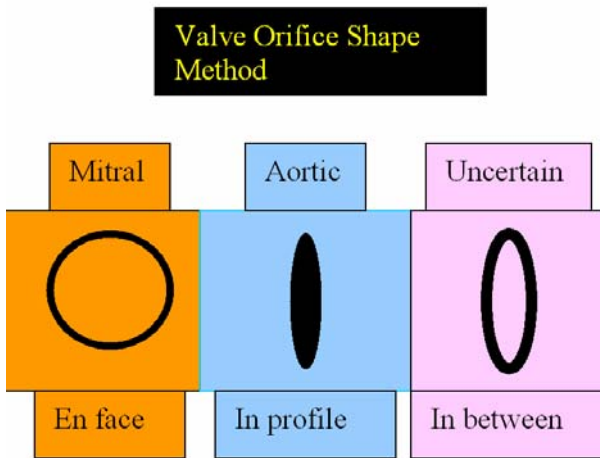
For each CXR, the reviewers commented whether a valve could be visualised on the film, and where one was detectable, made a judgement on the valve position, based on each of the four criteria referred to in the introduction which are presented diagrammatically in figure 1-4.



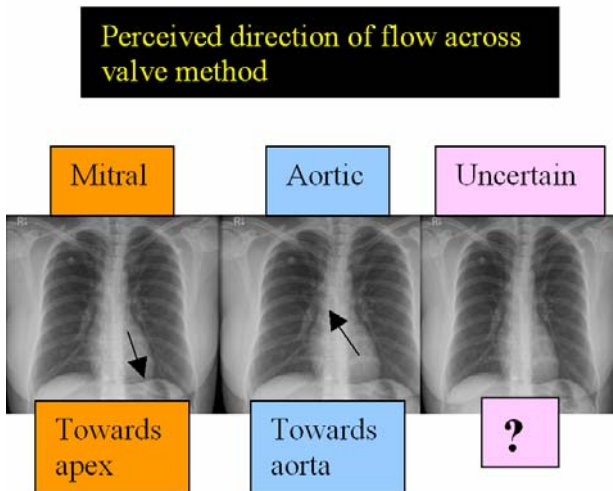
**Figure 1. Criterion 1.** If valve lies above line then it is aortic, if below line then mitral and uncertain if the line transects the prosthesis.



**Figure 2. Criterion 2.** If valve appears more vertical then mitral, if more horizontal then aortic and uncertain if it lies in between.



**Figure 3.** Criterion 3. If the valve orifice appears en face then it is mitral, if in profile for aortic and uncertain if in projects in between.



**Figure 4.** Criterion 4. If the perceived direction of blood flow appears to be across the valve toward the cardiac apex then it is mitral, if it is towards the ascending aorta then it is aortic, otherwise the position is uncertain.

For each criterion applied, the reviewers assigned a judgement as “aortic”, “mitral” or “uncertain” for each radiograph reviewed.

Data were tabulated using a Microsoft Excel spreadsheet. After coding, the author responsible for performing the statistical analysis verified the correct valve position for each subject from the cardiac surgical database. Sensitivities and specificities were calculated for each criteria based on each reviewers data.<sup>7</sup> In other words, a criterion would be highly sensitive if it could diagnose “aortic” valves when present and highly specific if it could diagnose when an aortic valve was not present (i.e. when a mitral valve was present). A

kappa statistic of inter-observer agreement was also calculated for each criterion.<sup>8</sup>

**RESULTS**

Two hundred and twenty seven CXR’s were evaluated by each of the reviewers.

The unblinded list of surgical procedures revealed that there were 174 aortic and 53 mitral valve replacements. Neither reviewer could identify a prosthesis on 8 CXR’s and were therefore unable to apply any criteria. These cases were excluded from statistical analysis, leaving 219 patients.

Table 1 indicates the number of cases where both reviewers were able to apply the rule being tested, having indicated that they thought it was either an “aortic” or “mitral” valve rather than “uncertain”. It can be seen that criterion one could be applied by both reviewers to less than 50% of X-rays. The other criteria could be applied by both reviewers to approximately 80% of films.

**Table 1.** Cases where both reviewers were able to apply the rule

	n	%
Criterion 1	101	37
Criterion 2	218	80
Criterion 3	218	80
Criterion 4	210	77

Table 2 presents the sensitivities and specificities for each criterion when applied by each reviewer, as well as the kappa statistic for inter observer agreement for each criterion.

**DISCUSSION**

There was a high level of inter-observer agreement for all four criteria applied to distinguish aortic from mitral valves prostheses.

Despite published data suggesting that normal thoracic landmarks were better visualised on digital, compared to conventional radiography,<sup>9</sup> Criterion 1 (imaginary line method), which is most well described in the literature, was unable to be applied by the reviewers to more than half of all the films, and even when it was applied had poor sensitivity in distinguishing aortic from mitral valves. This could be due to the fact that this differentiation originated from evaluation of erect PA films, whereas our study was of supine AP CXR’s. This result is also consistent with the results of Gross *et al.*<sup>6</sup> The explanation as to why the imaginary line method is poor on supine AP chest films is most likely due to a combination of two effects.

**Table 2. Sensitivities, specificities and inter-observer agreement**

	<i>Sensitivity (95% CI)</i>		<i>Specificity (95% CI)</i>		<i>Kappa</i>
	<b>Reviewer 1</b>	<b>Reviewer 2</b>	<b>Reviewer 1</b>	<b>Reviewer 2</b>	
Criterion 1	0.39 (0.31-0.47)	0.37 (0.25-0.50)	0.98 (0.91-1.00)	1.00 (0.93-1.00)	.966
Criterion 2	0.99 (0.96-1.00)	0.99 (0.97-1.00)	0.65 (0.53-0.76)	0.51 (0.38-0.64)	.785
Criterion 3	0.96 (0.92-0.98)	0.97 (0.93-0.98)	0.97 (0.90-0.99)	0.92 (0.83-0.97)	.943
Criterion 4	0.98 (0.95-0.99)	0.94 (0.89-0.96)	0.93 (0.84-0.97)	0.95 (0.87-0.98)	.846

Firstly, the weight of the abdominal contents tends to elevate the hemidiaphragms, decreasing the vertical dimensions of the mediastinum. This compressive effect distorts the mediastinal anatomy compared with an erect film. Secondly, due to beam geometry, an AP projection produces selective magnification of structures further away from the film (i.e. the anterior structures of the chest) and the diverging beam changes the projection of the diaphragm, distorting the apparent relative positions of the right costophrenic angle and the left hilum on the film. Crucially the other criteria used do not rely on the relationship between two widely separated anatomical structures and are therefore inherently more resistant to these effects.

The other 3 criteria were all highly sensitive in diagnosing the presence of an aortic valve. Of these methods, however, criterion 2 (orientation method) lacked specificity. Criterion 3 (valve orifice method) and 4 (perceived direction of blood flow method) were both highly sensitive and specific and thus appear to be the best tests for differentiating aortic from mitral prostheses. We therefore recommend using these criteria and exercising caution in the use of the other two methods. We also advocate a shift away from the "imaginary line method" on a PA CXR in day to day clinical practice and that intensive care trainees are made aware of the limitations of this approach. It should also be appreciated that these criteria may not be relevant in the setting of valve dysfunction (e.g. dehiscence).<sup>10</sup>

It was apparent to the reviewers after examining many films that other criteria, not formally tested, may also be of value. For example, a method involving the size of the prosthesis, with mitral valves being significantly larger than aortic prostheses, could be developed. This study also did not investigate the utility of methods to radiologically differentiate prostheses in the right heart or the presence of multiple prostheses.

In conclusion, we have demonstrated that the well known imaginary line method is of limited value when identifying prosthetic valve positions on supine AP

CXR's. This is of significance in critically ill patients in whom supine AP CXR are the norm. In the absence of surgical notes or a prosthesis identification cards issued upon discharge, fluoroscopy and echocardiography may also be of value in identifying valve location.

Received: 12 September 2005

Accepted: 9 October 2005

#### REFERENCES

1. Mehlman DJ, Resnekov L. A guide to the radiographic identification of prosthetic heart valves. *Circulation* 1978;57:613.
2. Mehlman DJ. A guide to the radiographic identification of prosthetic heart valves: an addendum. *Circulation* 1984;69:102-105.
3. Harrison EC, Rashtian MY, Allen DT, et al. An emergency physician's guide to prosthetic heart valves: identification and hemodynamic function. *Ann Emer Med* 1988;17:194-200
4. Worthley LIG. *Synopsis of Intensive Care Medicine*, Churchill Livingstone. Longman Group UK Ltd. 1994, p 63.
5. Talley NJ, O'Connor SO. *Clinical Examination: A systematic guide to physical diagnosis*. 4<sup>th</sup> edition; MacLennan and Petty Pty Ltd. 2001, p 92.
6. Gross BH, Shirazi KK, Slater AD. Differentiation of aortic and mitral valve prostheses based on postoperative frontal chest radiographs. *Radiology* 1983;49:389-391.
7. Confidence intervals for sensitivity and specificity were calculated at <http://www.pedro.fhs.usyd.edu.au/Utilities/CIcalculator.xls>
8. Kappa statistics were calculated at <http://www.chestx-ray.com/statistics/kappa.html>.
9. Konen E, Greenberg I, Rozenman J. Visibility of normal thoracic anatomic landmarks on storage phosphor digital radiography versus conventional radiography. *Isr Med Assoc J*. 2005;7:495-497.
10. Lewall DB, Ofole S, McCorkell SJ. Prosthetic heart valve malfunction: plain film findings. *Can Assoc Radiol J* 1988;39:182-185.