

Insertion Distance of Neonatal Intercostal Catheters Using a 10 French Argyle® Trocar Thoracic Catheter

M. W. DAVIES*†‡, K. R. DUNSTER†

*Grantley Stable Neonatal Unit, Royal Women's Hospital, Brisbane, QUEENSLAND

†Perinatal Research Centre, Royal Women's Hospital, Brisbane, QUEENSLAND

‡Department of Paediatrics & Child Health, University of Queensland, QUEENSLAND

ABSTRACT

Objective: We believed that intercostal catheters were often inserted too far into the thoracic cavity in neonatal patients. The aim of this study was to determine the average distance from the catheter tip to the midline, of intercostal catheters inserted in our neonatal unit and the incidence of catheters that were inserted too far into the thoracic cavity.

Methods: During a two year period we examined the chest X-rays of all infants who had an intercostal catheter inserted using an Argyle® 10 French trocar thoracic catheter for drainage of a pneumothorax. For each initial chest X-ray following the insertion of the intercostal catheter we measured the horizontal distance in mm from catheter tip to the midline. The tip to midline distance was zero if the tip was at the midline and negative if it crossed the midline. To standardise the tip to midline distance for different size infants we measured the distance in 'inter-vertebral' units.

Results: During the two year period, 13 of 24 intercostal catheters (54%) crossed the midline (i.e. were inserted too far). The mean (\pm SD) tip to midline distance was $-1.29 (\pm 13.9)$ mm with a range varying between -40 to 34 mm with a calculated 'inter-vertebral' units mean (\pm SD) tip to midline distance of $-0.32 (\pm 1.9)$ range -4.6 to 4.0 .

Conclusions: Fifty four percent of the intercostal catheters inserted in our unit were inserted too far. As the distance markings on the Argyle® intercostal catheters are marked from the last side-hole rather than from the tip of the catheter, Argyle® intercostal catheters may be inadvertently inserted two centimetres further than they should be. (**Critical Care and Resuscitation 2003; 5: 103-105**)

Key words: Intercostal catheters, complications, neonate, newborn

In a neonate, there is little guidance as to the optimal site to place an intercostal catheter (ICC) when draining a pneumothorax. Numerous complications have been reported after ICC insertion in neonates and it is considered prudent not to insert them too far to avoid damage to mediastinal structures.¹⁻³

We believed that the insertion of an ICC too far into the thoracic cavity occurred commonly and the aim of this study was to determine the intrathoracic position of an ICC when used in our neonatal unit.

METHODS

We examined the chest X-rays of all infants who had an ICC inserted for drainage of a pneumothorax in the intensive care nursery at the Royal Women's Hospital, Brisbane from 1.1.1999 to 31.12.2000. We only included the chest X-rays of those infants who had an ICC inserted in our unit. For any given infant we examined the first chest X-ray only after the first ICC insertion.

For each chest X-ray examined we determined the

Correspondence to: Dr. M. W. Davies, Department of Neonatology, Royal Women's Hospital, Herston, Brisbane, Queensland (e-mail: Mark_Davies@health.qld.gov.au)

intrathoracic position of the ICC. We measured the horizontal distance from catheter tip to the midline (measurement A in Figure 1). The tip to midline distance was zero if the tip was in the midline and negative if it crossed the midline. To standardise the tip to midline distance we measured the distance between the middle of the first (T_1) and the middle of the last (T_{12}) thoracic vertebrae (measurement B in Figure 1). This distance was divided by 11 to give the average inter-vertebral distance for each infant. The tip to midline distance divided by the average intervertebral

distance provided the tip to midline distance in 'intervertebral' units. This distance was then determined for each infant.

The ICC used during the study period in all infants was the Argyle® trocar thoracic catheter size 10 French (Argyle, Tyco Healthcare Group LP, Mansfield, Massachusetts, USA). The catheter was 3.3 mm in diameter and 23 cm long. They were usually placed in the 5th or 6th inter-costal space at, or just lateral to, the anterior axillary line. An ICC that crossed the midline was deemed to have been inserted too far.

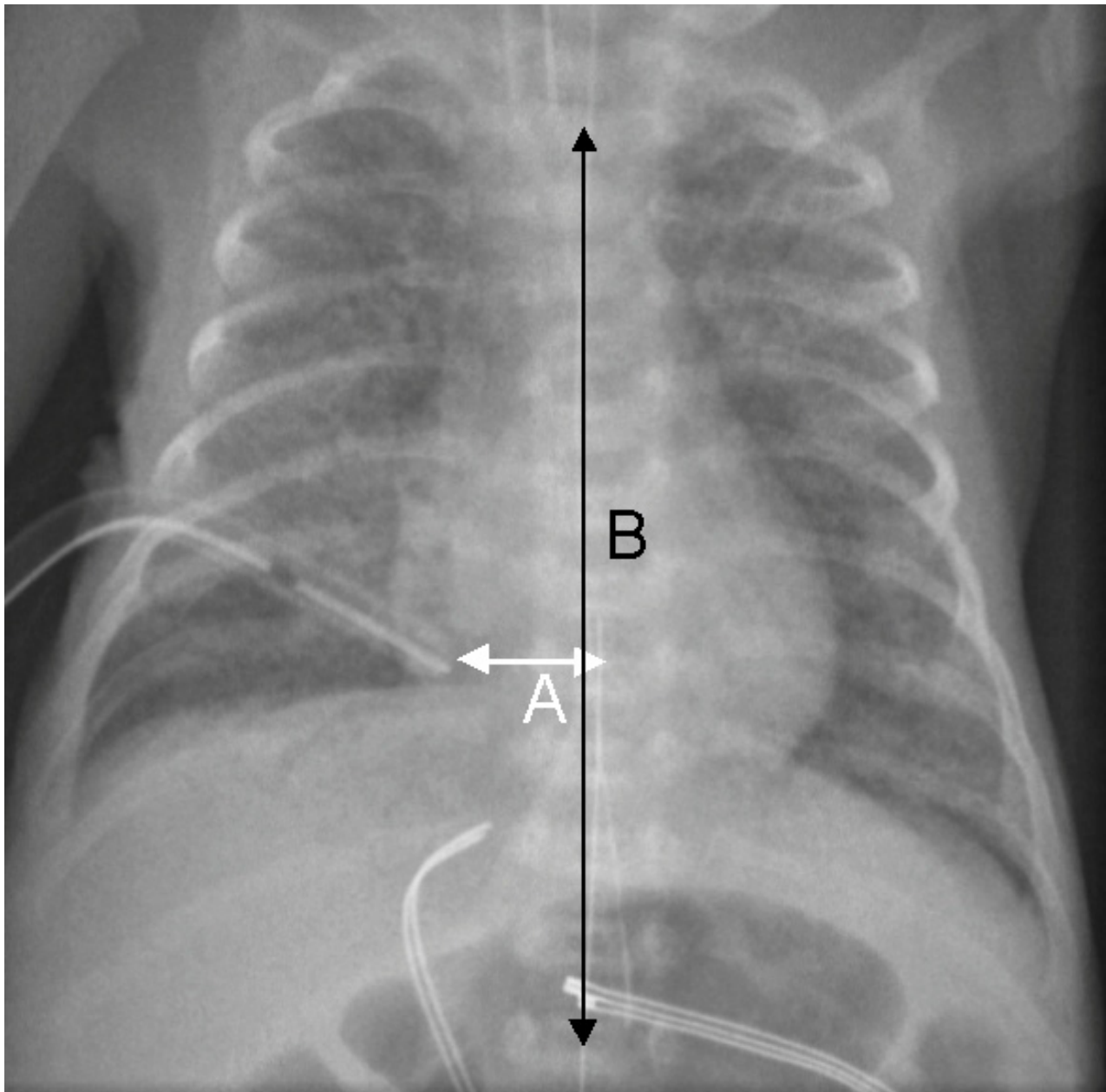


Figure 1. A chest X-ray of an infant with an inter-costal catheter in situ. Measurement A is the tip to midline distance. Measurement B is the distance from the middle of the first to the middle of the last thoracic vertebrae.

RESULTS

In the two year study period there were 24 infants with an ICC inserted for a pneumothorax in our neonatal unit whose chest X-rays were available for viewing. The mean (\pm SD) gestational age was 32.6 (\pm 6.0) weeks ranging from 22.5 to 41.4 weeks. The mean (\pm SD) birth weight was 2,030 (\pm 1,200) grams ranging from 415 to 4,130 grams.

Of the 24 ICCs that were inserted during this period, 13 (i.e. 54%) crossed the midline. None of the 24 ICCs that were inserted too far had any apparent associated complications and in none of the 24 cases was the drainage of air considered inadequate. The mean (\pm SD) tip to midline distance was -1.29 (\pm 13.9) mm ranging from -40 to 34 mm. The mean (\pm SD) tip to midline 'inter-vertebral unit' distance was -0.32 (\pm 1.9) units, ranging from -4.6 to 4.0 units. The frequency distribution of ICCs at various distances from the midline is shown in the histogram in Figure 2. The tip to midline distance is distributed normally about the midline (Kolmogorov-Smirnov normality test, P value > 0.15).

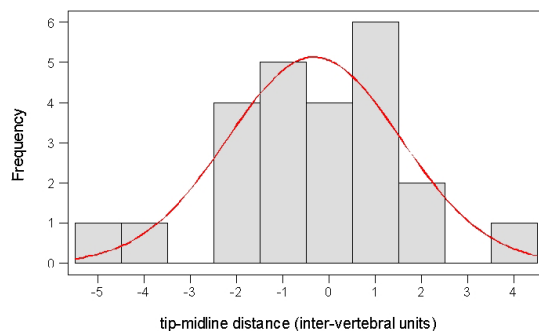


Figure 2. The frequency distribution showing the number of intercostal catheters at various distances from the midline.

DISCUSSION

If an ICC that crosses the midline is considered to be inserted too far then we confirmed that just over half of the ICCs inserted into neonates in our unit are inserted too far. Possible complications that might arise from an ICC that encroaches on midline structures in the thorax include phrenic nerve palsy,² Horner's syndrome⁴ and penetration of the mediastinum and/or pericardium.³

We believe that one of the reasons for ICCs being inserted too far in our unit is that the numeric depth marks on the Argyle® catheter used, are measured from the last side hole which is 2 centimetres from the catheter tip. Other catheters that are commonly used in

neonatal intensive care units (such as umbilical catheters and percutaneous long-lines) have their length marked from the catheter tip. With the Argyle® catheter there is no indication on the catheter packaging or the manufacturer's web-site⁵ that the numeric depth marks indicate distance from the last side-hole and not the tip. If this difference is not realised at the time of an Argyle® catheter insertion, the operator may believe mistakenly that the catheter is inserted two centimetres less than it is, which may explain the incidence of ICCs being inserted too far in our study. In our report, if two centimetres were removed from the tip to midline distance, only one of the 24 ICCs would have crossed the midline.

Whilst the correct position for ICC placement when draining pneumothoraces has not been well studied, it would seem prudent to avoid midline structures. Odita *et al*,² recommend that that the ICC tip should be no less than one centimetre from the spine or mediastinum. This becomes important if an ICC is incorrectly placed posterior to the lung as it may damage posterior mediastinal contents.

In summary, 54% of the ICCs inserted in our unit were inserted too far. We believe that clinicians may not be aware that the distance markings on the Argyle® ICC are marked from the last side-hole and may therefore inadvertently insert Argyle® ICCs two centimetres further in than they think they should be.

Received: 12 March 2003

Accepted: 24 April 2003

REFERENCES

1. Jung AL, Minton SD, Roan Y. Pulmonary haemorrhage secondary to chest tube placement for pneumothorax in neonates. *Clin Pediatr* 1980;19:624-627.
2. Odita JC, Khan ASSI, Dincsoy M, Kayyali M, Masoud A, Ammari A. Neonatal phrenic nerve paralysis resulting from intercostal drainage of pneumothorax. *Pediatr Radiol* 1992;22:379-381.
3. Allen RW, Jung AL, Lester PD. Effectiveness of chest tube evacuation of pneumothorax in neonates. *J Pediatr* 1981;99:629-634.
4. Rosegger H, Fritsch G. Horner's syndrome after treatment of tension pneumothorax with tube thoracostomy in a newborn infant. *Eur J Pediatr* 1980;133:67-68.
5. Tyco healthcare, Kendall. Argyle thoracic catheters. <http://www.kendallhq.com/catalog/prodlisting.asp> (accessed April 22, 2003)