

## Practice tips

# Percutaneous Tracheostomy

L. I. G. WORTHLEY, A. W. HOLT

Department of Critical Care Medicine, Flinders Medical Centre, Adelaide, SOUTH AUSTRALIA

---

### ABSTRACT

**Objective:** To review the indications and complications of the percutaneous tracheostomy compared with the standard surgical tracheostomy in the critically ill patient.

**Data sources:** A review of studies reported from 1966 to 1998 and identified through a MEDLINE search on percutaneous tracheostomy.

**Summary of review:** A tracheostomy is often performed in the critically ill patient when airway access, airway protection and mechanical ventilation are required for a prolonged period. The percutaneous dilatational technique rather than the standard surgical technique is now often used as it can be easily and rapidly performed at the bedside. The two percutaneous tracheostomy procedures most often used are the progressive dilatational and the guide wire dilatational forceps techniques. The complications associated with both methods include misplacement of the insertion needle, Seldinger wire or dilator, insertion failure, fracture of the tracheal ring, bleeding, barotrauma, bacteraemia and death. The incidence of these complications often depends on the experience of the operator and while bronchoscopic guidance has been used to reduce the number of complications, it prolongs the procedure, requires a separate operator and may cause hypercapnoea.

**Conclusions:** In the critically ill patient who requires a tracheostomy, the percutaneous rather than the standard surgical technique is the method of choice as it can be performed at the bedside, leaves a smaller scar after decannulation and may be associated with fewer complications compared with the standard surgical technique. (**Critical Care and Resuscitation 1999; 1: 101-109**)

**Key words:** Intensive care, surgery, tracheostomy, percutaneous, complications

---

Tracheostomy is indicated when airway protection, airway access or mechanical ventilation are required for prolonged periods<sup>1-4</sup> and in many critical care units the percutaneous tracheostomy has become the technique of choice.<sup>5-9</sup>

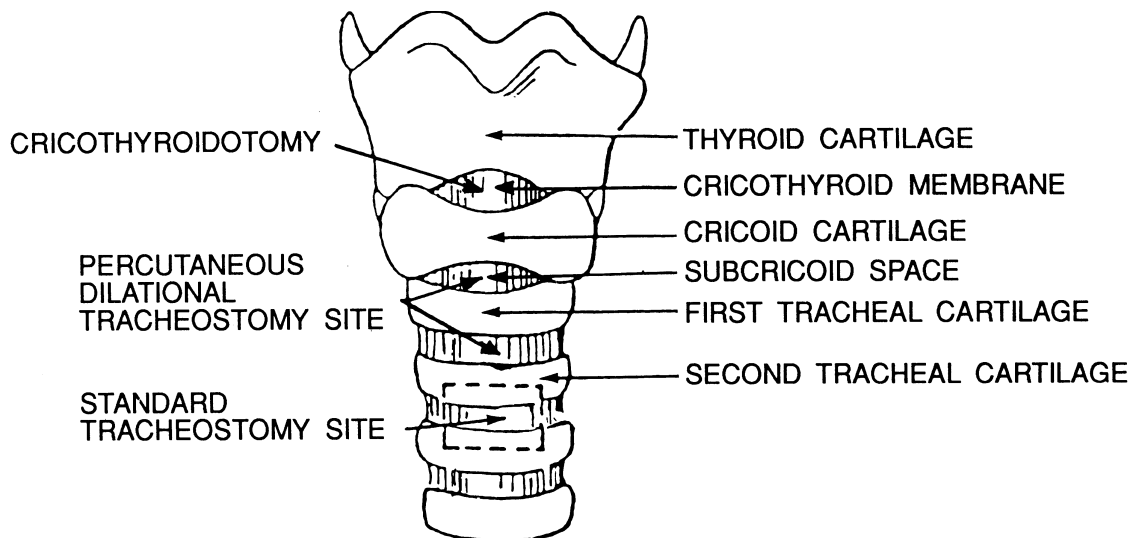
Previously, when a tracheostomy was required a standard surgical tracheostomy was performed, usually in the operating theatre and under general anaesthesia by a technique that had not altered markedly since Jackson's description in 1909.<sup>10</sup> The procedure involved making a 4 - 5 cm horizontal or vertical cutaneous incision over the second or third tracheal rings, dividing

the subcutaneous tissue, separating the strap muscles, identifying and ligating the thyroid isthmus and cauterizing and ligating the relevant anterior jugular and thyroid veins. A vertical or horizontal incision or a window was then cut between the second and third tracheal rings to allow the insertion of a tracheostomy tube (Figure 1).<sup>1-3,10</sup>

A modification known as the Bjork flap (suturing the tip of an inverted 'U' flap, fashioned from the anterior trachea to the lower skin surface)<sup>11</sup> has also been used, to provide a tracheal stoma to facilitate tracheostomy tube replacement if it became dislodged.<sup>12</sup>

---

Correspondence to: Dr. L. I. G. Worthley, Department of Critical Care Medicine, Flinders Medical Centre, Bedford Park, South Australia 5042 (e-mail: [lindsay.worthley@flinders.edu.au](mailto:lindsay.worthley@flinders.edu.au))



**Figure 1.** A diagram of the larynx and trachea indicating the sites of tracheal tube insertion for cricothyrotomy, surgical tracheostomy and percutaneous tracheostomy.

However, in the critically ill patient requiring a tracheostomy the percutaneous technique is more easily and quickly performed at the bedside and may even be safer when compared with the standard surgical technique.

The percutaneous tracheostomy tube insertion is usually carried out electively in an intubated patient, although it has been performed as an emergency under local anaesthesia in a patient with acute airway obstruction.<sup>13,14</sup>

#### PERCUTANEOUS TRACHEOSTOMY TECHNIQUES

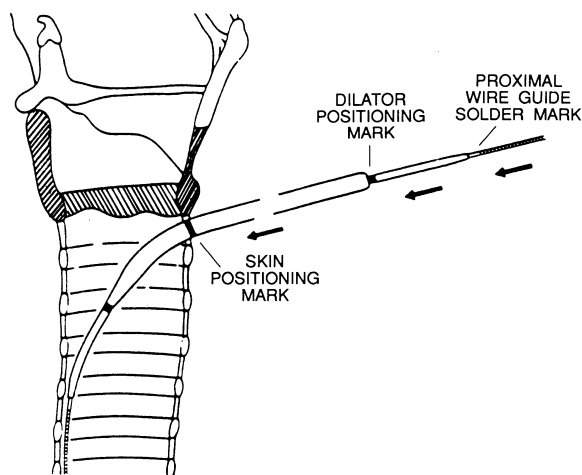
There have been many percutaneous tracheostomy techniques described, although the differences between the various methods essentially relate to differences in;

- the methods of airway control during the procedure (e.g. withdrawing endotracheal tube until the cuff is just visible at the cords,<sup>15</sup> completely withdrawing the endotracheal tube and placing the tip of the tube in the glottis, reinflating the cuff and wedging it into the opening of the larynx,<sup>9</sup> laryngeal mask<sup>16</sup>, Combitube<sup>17</sup>),
- identifying the trachea (e.g. aspirating needle,<sup>5,6</sup> Seldinger wire,<sup>8,13,18</sup> bronchoscopic visualization,<sup>19</sup> or bronchoscopy with transtracheal illumination<sup>20</sup>),
- forming the tracheal stoma (e.g. progressive dilators,<sup>7</sup> or single dilation using, forceps,<sup>9</sup> tracheostome,<sup>8</sup> cutting trocar<sup>5,6</sup>) and/or
- inserting the tracheostomy tube (e.g. blindly<sup>6</sup> or guided by a trocar,<sup>5</sup> introducer,<sup>7</sup> or Seldinger wire<sup>9</sup>).

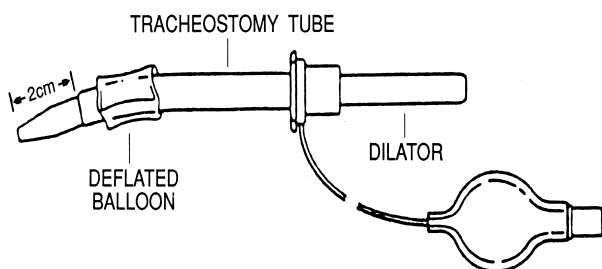
Sheldon et al, first described a percutaneous tracheostomy technique 25 years ago which required a special needle to identify the trachea and a one-stage insertion of the tracheostomy tube using a cutting trocar.<sup>5</sup> Toye and Weinstein described a similar technique using a split needle to identify the trachea. The tracheostomy tube was introduced into the trachea using a dilator inserted through the side of the tracheostomy tube and guided into the trachea by a filiform portion of the dilator tip.<sup>6,21</sup> However, both techniques have not gained wide acceptance.

A one-stage dilation technique proposed by Schachner et al has also been described and marketed as the 'Rapitrac'. It uses a sharp straight-armed and bevel-tipped dilating tool that passes over a guide wire into the trachea where the tip is opened to form a tracheal stoma, allowing the tracheostomy tube to be inserted.<sup>8,22</sup> The sharp tip of this instrument and the requirement for the instrument to remain in place while the tracheostomy tube is placed blindly into the trachea have been responsible for many complications, including tracheostomy tube insertion failure, tube malplacement, cuff rupture, pneumothoraces, mediastinal emphysema, subcutaneous emphysema and even death.<sup>23,24</sup> It now appears that the 'Rapitrac' has been withdrawn from the market.

The progressive dilation method described by Ciaglia et al<sup>17</sup> is currently the most popular percutaneous tracheostomy technique.<sup>25-27</sup> A Seldinger guidewire with a Teflon cannula is inserted into the trachea between the cricoid and the first tracheal ring or between the first and second tracheal rings and is used to guide a series of dilators to create a tracheostomy stoma for the tracheostomy tube (Figures 2 and 3).<sup>7</sup>



**Figure 2.** Diagram indicating the correct position of the tracheal dilating assembly (Modified from Ciaglia P, Graniero KD. *Chest* 1992;101:464-468)



**Figure 3.** Tracheostomy tube and dilator ready for tracheal insertion (Modified from Ciaglia P, Graniero KD. *Chest* 1992;101:464-468)

As the dilators form a hole in the trachea by splitting the trachea laterally, and as 5-7 dilators are needed (each of which prolongs the procedure and therefore the duration of a compromised airway), methods to augment the lateral split of the trachea (e.g., using a modified nasal speculum), have been proposed by Ciaglia *et al*, to facilitate the formation of the tracheal stoma.<sup>18</sup>

The more recent one-stage dilation technique proposed by Griggs *et al*, uses of a pair of modified Howard-Kelly forceps (e.g. the curve of the jaws is increased, a central guidewire hole is drilled from the tip to the midpoint of the arms, and the tip is narrowed, rounded and tapered) to facilitate the formation of the tracheal stoma by promoting the tracheal membrane split and thereby increase the speed of tracheostomy insertion.<sup>9</sup> The modified forceps (or guide wire dilator forceps) have been marketed by Portex® with a pre-packaged kit.

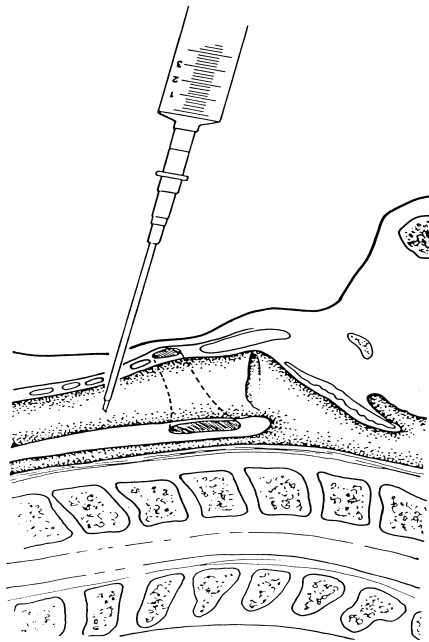
While some have confused the ‘Rapitrac’ dilator with the guide wire dilator forceps,<sup>28,29</sup> the two instruments are fundamentally very different. The ‘Rapitrac’ uses a straight-arm, sharp-tip cutting instrument that also serves as a dilator for the tracheostomy tube insertion, whereas the guide wire dilator forceps are a curved, rounded and blunt tipped instrument that are used to facilitate the lateral split in the tracheal membrane.

The guide wire dilator forceps can also be used with a pre-packaged Cook kit (Cook® CPTS-100 Worthley 121989; which contains a small dilator, 0.052mm J-tipped guidewire, a Teflon cannula and a trocar, to allow a size 8 or 9 mm internal diameter Portex® tracheostomy tube to be inserted). The forceps facilitate the formation of the tracheal stoma, and the longer trocar and Teflon supported guidewire reduces the possibility of posterior tracheal damage and tracheostomy misplacement.

Using the latter technique (and with a separate operator managing the airway, as described later) the anterior neck is prepared and draped, the cricoid cartilage is identified and lignocaine 1% with adrenaline 1:200,000 is injected immediately below the cricoid. A 1.5 to 2 cm midline transverse cutaneous incision is made at this level and, with blunt dissection using a mosquito clamp, the anterior neck structures between the incision and the trachea are separated. A 14 gauge needle and cannula with a fluid filled syringe attached, is inserted in the midline of the incision and directed posteriorly whilst withdrawing the plunger of the attached syringe. The other hand of the operator steadies the larynx and trachea to ensure that the needle remains in the midline. The needle is directed to pass between the first and second tracheal rings or between the second and third tracheal rings (Figure 4), rather than between the cricoid and the first tracheal ring as originally described by Ciaglia (as this has been associated with a high incidence of cricoid fracture<sup>30</sup>).

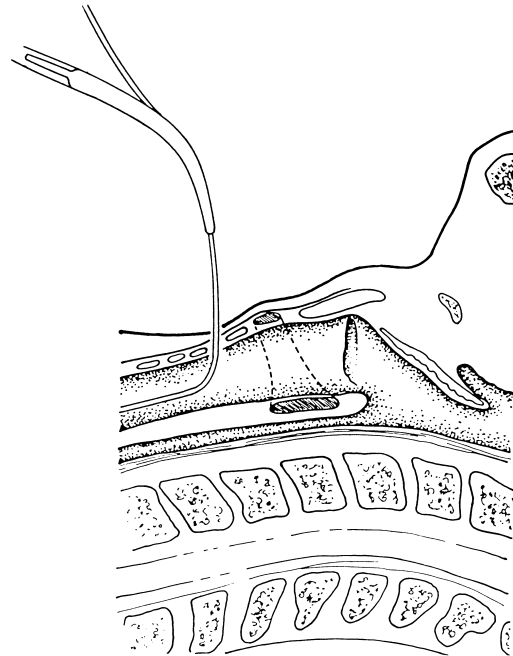
As soon as air begins to bubble into the syringe, the outer plastic cannula is advanced into the lumen of the trachea and the inner needle is removed. The fluid filled syringe is then attached to the cannula and air is withdrawn to confirm placement of the cannula into the trachea (if air cannot be withdrawn, withdraw the cannula slightly until air can be withdrawn otherwise reinsert the cannula).

A J-tipped Seldinger wire is introduced into the trachea and the plastic cannula is removed leaving the Seldinger wire in place (Figure 5). A small black dilator is then inserted into the trachea over the Seldinger wire to enlarge the hole in the anterior tracheal membrane.

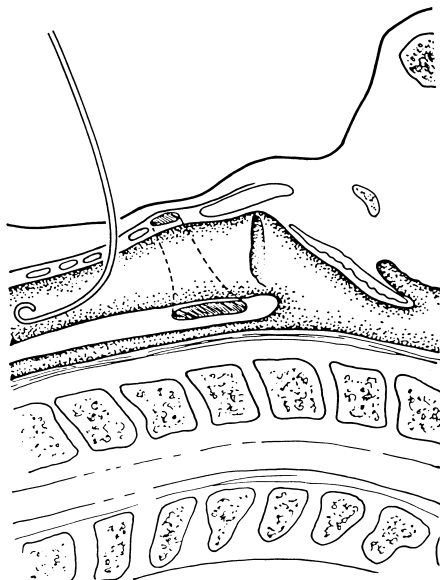


**Figure 4.** Insertion of a 14 gauge needle and cannula into the trachea.

along the wire through the soft tissues of the neck piercing the anterior tracheal membrane and entering the trachea where they are opened to the same diameter as the skin incision to split the tracheal membrane laterally (Figure 7).

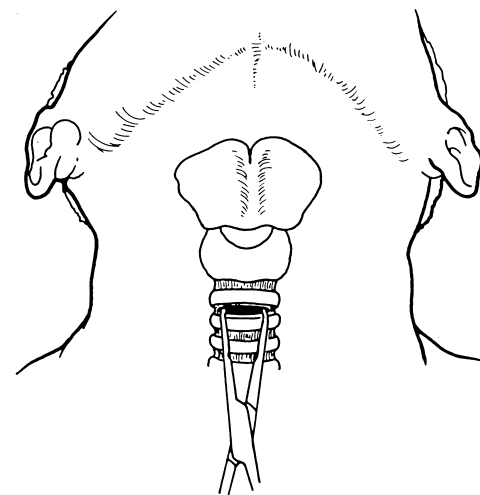


**Figure 6.** Insertion of the guide wire dilation forceps along the Seldinger wire.



**Figure 5.** Insertion of the Seldinger wire into the trachea

The dilator is removed and the tip of the Seldinger wire is passed through a closed tip of the guide wire dilator forceps (Figure 6). The forceps are advanced

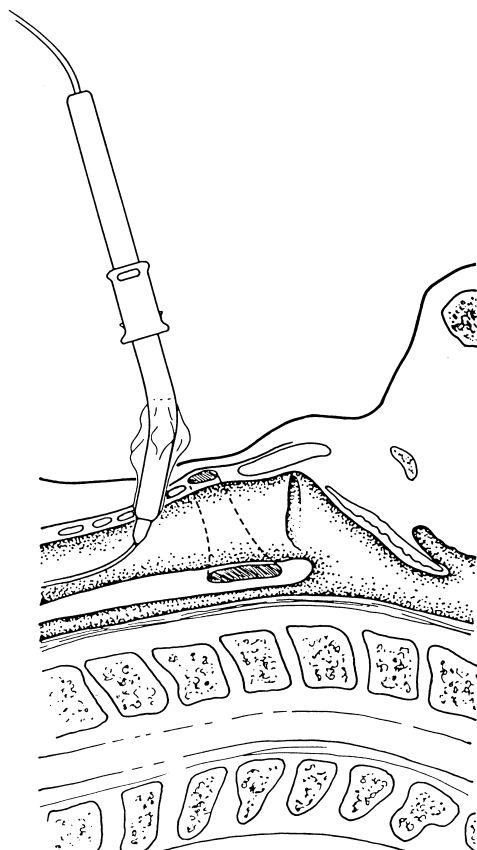


**Figure 7.** Splitting the tracheal membrane with the guide wire dilation forceps.

A two stage dilation procedure may also be used, opening the blades in front of the trachea first to dilate the pretracheal tissues before inserting the guide wire

dilator forceps into the trachea to dilate the trachea.<sup>31,32</sup>

A previously prepared tracheostomy tube and dilating assembly are then inserted over the guide wire and advanced into the trachea (Figure 8). The dilating assembly and guide wire are removed, the tracheostomy tube cuff is inflated and the appropriate breathing circuit is connected. Subcutaneous bleeding stops with the lateral pressure applied by the tracheostomy tube and the inflated cuff anchors the tube securely in place.



**Figure 8.** Insertion of the tracheostomy tube and trocar into the trachea

This technique permits the insertion of tracheostomy tubes up to 36 - 39 French,<sup>9</sup> and can be performed in less than half the time compared with the progressive dilatational method<sup>33</sup> (e.g. within 30 seconds following skin incision or within 5 minutes of the decision to perform the tracheostomy).<sup>34</sup>

Bronchoscopic visualisation of the insertion of the insertion needle, Seldinger wire and tracheostomy has been used by some authors to reduce the incidence of insertion failure<sup>19,20,35</sup>. We initially used bronchoscopic visualization to confirm the Seldinger wire and tracheal tube placement (and were surprised at how much antero-

posterior compression occurred during the insertion of the 14 gauge needle and cannula into the trachea, and how often the Seldinger wire was inserted 'off centre'). However, bronchoscopy during the whole procedure can reduce the patient's ventilation and significant hypercapnoea has been reported with its use.<sup>36</sup> It also requires three clinicians to be present to safely perform the operation. We now only use bronchoscopic confirmation when we are unsure of the placement of the Seldinger wire. Some also use bronchoscopy during the learning phase of the technique (e.g. during the first 5-10 percutaneous tracheostomies), to allow the operator who is being taught, to become confident with the procedure.

#### AIRWAY AND VENTILATION MANAGEMENT

During the percutaneous tracheostomy procedure, an assistant is required to continually monitor (using pulse oximetry and end expired carbon dioxide) and manage the airway (the patient is often paralysed, sedated and mechanically ventilated with an FIO<sub>2</sub> of 100%). While the surgical tracheostomy technique requires the endotracheal tube to be withdrawn after the stoma has been fashioned, percutaneous tracheostomy techniques require the endotracheal tube to be withdrawn from the site of insertion before the stoma is formed to ensure that the operator has free access to the tracheal lumen at all times.

The upper airway is suctioned and the cuff of the endotracheal tube is deflated. The endotracheal tube is withdrawn (under direct vision using a laryngoscope) until the cuff lies above the vocal cords. The cuff is inflated and gently wedged into the glottic opening and held in position by the assistant during the procedure. Adequacy of the seal and thus ventilation is constantly monitored using expired tidal volumes and pulse oximetry.

#### EARLY COMPLICATIONS (WITHIN THE FIRST 24 HOURS)

##### Technical problems

*Insertion failure:* Failure to insert the tracheostomy tube appears to be greater with percutaneous tracheostomy techniques that do not use a tracheal guidewire. Failure to replace a tracheostomy tube, however, may occur with any percutaneous tracheostomy method as all techniques produce a small tracheal stoma and provision to redilate the stoma should be available when changing the tracheostomy tube.

*Misplacement of insertion needle, Seldinger wire or dilators:* Misplacement of the needle, Seldinger wire or dilators into carotid artery, jugular vein, tracheal ring,

oesophagus, paratracheal tissues, endotracheal tube, cuff or Murphy's eye have all been reported.<sup>15,37,38</sup>

**Tracheal tube misplacement:** Tracheal tube misplacement into the paratracheal tissues, posterior tracheal wall, oesophagus and intrapleural spaces<sup>39</sup> have all been reported with percutaneous tracheostomy insertion, the incidence of which varies depending on the technique used (the techniques of Schachner et al and of Toye and Weinstein have a higher incidence of tracheal tube misplacement,<sup>6,8,9,23</sup> when compared with other percutaneous tracheostomy techniques.<sup>18,34</sup>) and experience of the operator.

**Tracheal tube cuff rupture:** A high incidence of tracheostomy tube cuff rupture during insertion has been reported with the percutaneous technique of Schachner et al<sup>8,23</sup>

### Fracture of tracheal ring

During tracheal dilation a tracheal ring fracture commonly occurs (e.g. 30% - 90%)<sup>30,40,41</sup> which can lead to scarring, web, spicule or stenosis formation within the trachea or tracheomalacia, causing upper airway obstruction during decannulation. The lesion that one is wishing to achieve during dilation is an anterior split in the tracheal membrane between the rings of the cartilage.

### Haemorrhage

Unlike surgical tracheostomy, the technique of percutaneous tracheostomy does not provide controlled haemostasis and one of the common complications associated with this technique is haemorrhage. The bleeding usually stops with lateral pressure applied by the tracheostomy tube or with direct pressure applied to the lateral walls of the tracheal stoma. However, if a large vessel has been pierced (e.g. anterior jugular or thyroid veins) or the patient has a bleeding disorder, the haemorrhage may be profuse. If bleeding does not stop, one should reinsert the endotracheal tube, place the cuff over the tracheostomy stoma, and apply direct pressure over the stoma. If this does not control the bleeding surgery is required.<sup>34</sup>

### Barotrauma

The method of Schachner et al has a higher incidence of barotrauma (e.g. subcutaneous emphysema, mediastinal emphysema, pneumo-thorax),<sup>8,23</sup> when compared with other percutaneous tracheostomy tube techniques.<sup>18,34</sup>

### Bacteraemia

One study demonstrated a 10% incidence of bacteraemia (predominantly *Staphylococcus epidermidis*) following percutaneous tracheostomy,<sup>42</sup>

implying that patients with a high risk of endocarditis (e.g. prosthetic or damaged cardiac valves) should be treated with prophylactic antibiotic therapy before the operation.

### Death

There have been at least five recorded deaths associated with the percutaneous tracheostomy technique, which is usually due to misplaced tracheostomy tube insertion, premature decannulation or haemorrhage, with associated hypoxia and cardiac arrhythmia.<sup>21,24,43-45</sup>

### LATE COMPLICATIONS (AFTER THE FIRST 24 HOURS)

Late complications include wound infection, wound breakdown, scarring with skin tethering,<sup>46</sup> tracheal stenosis, tracheomalacia, delayed haemorrhage, tracheo-innominate fistula and tracheo-oesophageal fistula. The complications of infection, wound breakdown and scarring with skin tethering are usually less with the percutaneous tracheostomy technique when compared with the surgical tracheostomy technique.<sup>18,34</sup> Tracheal stenosis, tracheomalacia, tracheo-innominate fistula and tracheo-oesophageal fistula are usually rare complications.<sup>18,43,47,48</sup>

Delayed haemorrhage may also occur (usually from anterior jugular or thyroid veins) particularly in patients who have a secondary haemostatic defect (e.g. in patients with multiple organ failure, renal failure, hepatic failure or trauma) and can lead to a life threatening complication of airway obstruction.<sup>49</sup> An unusual manifestation of this complication is the development of a 'ball valve' clot obstruction to the tracheostomy tube.<sup>50</sup> The patient usually has had a continuous oozing from the tracheostomy site despite treatment with local thrombin or adrenaline, stomal packing or sutures and the problem surfaces when there appears to be some difficulty in mechanical ventilation (usually difficulty with expiration which may be mistaken as bronchospasm) and difficulty in suctioning.

The problem of a tracheal clot may be diagnosed with a bronchoscope, however if there is an acute obstruction, the tracheostomy must be taken out immediately and the patient intubated with an endotracheal tube (the ball valve clot usually 'pops' out the tracheal stoma with removal of the tracheostomy tube).

If the clot remains, then it needs to be removed which may require a rigid bronchoscope and large bore suction catheter.

### CONTRAINDICATIONS

Some believe that the percutaneous tracheostomy

should not be performed in the presence of marked anatomical abnormalities (e.g. goiter), uncorrected coagulopathies, or in children, although a percutaneous tracheostomy has been performed in all these subgroups.<sup>51</sup> A large goiter, however, still remains a relative contraindication.

#### COMPARISON BETWEEN PERCUTANEOUS AND SURGICAL TRACHEOSTOMY

In a prospective randomised trial reported by Hazard et al, surgical tracheostomies were associated with a least one complication in 58% (14/24), compared with 25% (6/24) in the percutaneous dilatation tracheostomy group.<sup>52</sup>

In a prospective non-randomized study reported by Griggs et al, 18.9% (14/74) of the surgical tracheostomies were associated with complications compared with 3.9% (6/153) of the one stage dilatational percutaneous tracheostomies.<sup>34</sup> The lower incidence of complications in the percutaneous tracheostomy group in this study was due largely to a lower incidence of wound infection and wound breakdown associated with the smaller tracheal stoma.<sup>34</sup> In a prospective randomised study reported by Holdgaard et al, there was a significant increase in infection and minor bleeding in the surgical tracheostomy group compared with the percutaneous tracheostomy group.<sup>53</sup>

The time taken for a percutaneous tracheostomy ranges from 1 to 20 minutes<sup>34</sup> whereas the time taken to perform the surgical tracheostomy ranges from 15 - 60 minutes. The need to transport a patient from the critical care unit to the operating theatre has often been cited as an unnecessary source of complications, with one study finding at least one mishap in one third of patients during the patient transport.<sup>54</sup> However, another study of 100 patients requiring surgical tracheostomy found no complications relating to patient transport.<sup>55</sup>

Most studies show that percutaneous tracheostomy is superior to operative tracheostomy, particularly in relation to cost, convenience and complication rate in the critically ill patient,<sup>56,57</sup> although some believe that apart from cost and convenience, there may be little difference between the two techniques.<sup>28,58</sup> The complications reported with surgical tracheostomy and percutaneous tracheostomy and their reported frequencies<sup>2,4,59-62</sup> are listed in Table 1.

#### SUMMARY

In the critically ill patient the percutaneous tracheostomy is the tracheostomy technique of choice.<sup>13,18,34,52,53</sup> While there are differences between the various methods, the dilatational technique is commonly used. It can be performed rapidly and easily at the bedside, is associated with fewer complications,

and after decanulation it leaves the patient with a smaller scar than the standard surgical tracheostomy.

**Table 1. Tracheostomy complications**

	<i>Percutaneous</i> (%)	<i>Surgical</i> (%)
Barotrauma		
Pneumothorax	0-2	0-4
Subcutaneous emphysema	0-10	2-15
Tube malplacement	0-6	0-7
Failure of insertion	0-8	0-1
Stomal complications		
primary haemorrhage	3-30	2-20
secondary haemorrhage	0-6	1-5
infection	0-2	6-40
stenosis	0-1	0-1
wound breakdown	0	4-15
Mortality	0.3-1	0-5
Total complication rate	3-25	6-66

Received: 20 October 1998

Accepted: 10 November 1998

#### REFERENCES

1. Heffner JE, Miller KS, Sahn SA. Tracheostomy in the intensive care unit. Part 1: indications, technique, management. *Chest* 1986;90:269-274.
2. Timmis HH. Tracheostomy: an overview of implications, management and morbidity. *Adv Surg* 1973;7:199-233.
3. Hardy KL. Tracheostomy: indications, techniques, and tubes. A reappraisal. *Am J Surg* 1973;126:300-307.
4. Heffner JE, Miller KS, Sahn SA. Tracheostomy in the intensive care unit. Part 2: complications. *Chest* 1986;90:430-436.
5. Sheldon CH, Pudenz RH, Tichy FY. Percutaneous tracheostomy. *JAMA* 1957;165:2068-2070.
6. Toye FJ, Weinstein JD. A percutaneous tracheostomy device. *Surgery* 1969;65:384-389.
7. Ciaglia P, Firsching R, Syniec C. Elective percutaneous dilatational tracheostomy. *Chest* 1985;87:715-719.
8. Schachner A, Ovil Y, Sidi J, Rogev M, Heilbronn Y, Levy MJ. Percutaneous tracheostomy-A new method. *Crit Care Med* 1989;17:1052-1056.
9. Griggs WM, Worthley LIG, Gilligan JE, Thomas PD, Myberg JA. A simple percutaneous tracheostomy technique. *Surg Gynecol Obst* 1990;170:543-545.
10. Jackson C. Tracheostomy. *Laryngoscope* 1909;19:285-290.
11. Bjork VO. Partial resection of the only remaining lung with the aid of respirator treatment. *I Thorac Cardiovasc Surg* 1960;39:179-188.
12. Price DG. Techniques of tracheostomy for intensive care unit patients. *Anaesthesia* 1983;38:902-904.

13. Griggs WM, Myburgh JA, Worthley LIG. Urgent airway access-an indication for percutaneous tracheostomy. *Anaesth Intens Care* 1991;19:586-587.
14. Dob DP, McLure HA, Soni N. Failed intubation and emergency percutaneous tracheostomy. *Anaesthesia* 1998;53:69-78.
15. Hill SA. An unusual complication of percutaneous tracheostomy. *Anaesthesia* 1995;50:469-470.
16. Verghese C, Rangasami J, Kapila A, Parke T. Airway control during percutaneous dilatational tracheostomy: pilot study with the intubating laryngeal mask airway. *Br J Anaesth* 1998;81:608-609.
17. Mallick A, Quinn AC, Bodenham AR, Vucevic M. Use of the Combitube for airway maintenance during percutaneous dilatational tracheostomy. *Anaesthesia* 1998;53:249-255.
18. Ciaglia P, Graniero KD. Percutaneous dilatational tracheostomy. Results of a long term follow-up. *Chest* 1992;101:464-468.
19. Griggs WM, Worthley LIG, Myburgh JA. Percutaneous tracheostomy (surgical pros and cons). *Surg Gynecol Obst* 1990;171:511-513.
20. Marelli D, Paul A, Manolidis S, et al. Endoscopic guided percutaneous tracheostomy: early results of a consecutive trial. *J Trauma* 1990;30:433-435.
21. Toye FJ, Weinstein JD. Clinical experience with percutaneous tracheostomy and cricothyrotomy in 100 patients. *J Trauma* 1986;26:1034-1040.
22. Schachner A, Ovil J, Sidi J, Avram A, Levy MJ. Rapid percutaneous tracheostomy. *Chest* 1990;98:1266-1270.
23. Hutchinson RC, Mitchell RD. Life-threatening complications from percutaneous dilatational tracheostomy. *Crit Care Med* 1991;19:118-120.
24. Ivatury R, Siegel JH, Stahl WM, Simon R, Scorpio R, Gens DR. Percutaneous tracheostomy after trauma and critical illness. *J Trauma* 1992;32:133-140.
25. Cook PD, Callanan VI. Percutaneous dilatational tracheostomy technique and experience. *Anaesth Intens Care* 1989;17:456-457.
26. Holtzman RB. Percutaneous approach to tracheostomy. *Crit Care Med* 1989; 17: 595.
27. Hazard PB, Garrett HE, Adams JW, Robins ET, Aguillard RN. Bedside percutaneous tracheostomy: experience with 55 elective procedures. *Ann Thor Surg* 1988;46:63-67.
28. Powell DM, Price PD, Forrest A. Review of percutaneous tracheostomy. *Laryngoscope* 1998;108:170-177.
29. Law RC, Carney AS, Manara AR. Long-term outcome after percutaneous dilatational tracheostomy. Endoscopic and spirometry findings. *Anaesthesia* 1997;52:51-56.
30. Van Heurn LWE, Theunissen PHMH, Ramsay G, Brink PRG. Pathologic changes of the trachea after percutaneous dilatational tracheostomy. *Chest* 1996;109:1466-1469.
31. Caldicott LD, Oldroyd GJ, Bodenham AR. An evaluation of a new percutaneous tracheostomy kit. *Anaesthesia* 1995;50:49-51.
32. Van Heerden PV, Webb SA, Power BM, Thompson WR. Percutaneous dilatational tracheostomy--a clinical study evaluating two systems. *Anaesth Intensive Care* 1996;24:56-59.
33. McLure HA, Dob DP, Mannan MM, Soni N. A laboratory comparison of two techniques of emergency percutaneous tracheostomy. *Anaesthesia* 1997;52:1199-1201.
34. Griggs WM, Myburgh JA, Worthley LIG. A prospective comparison of a percutaneous tracheostomy technique with standard surgical tracheostomy. *Intens Care Med* 1991;17:261-263.
35. Fernandez L, Norwood S, Roettger R, Gass D, Wilkins H 3rd. Bedside percutaneous tracheostomy with bronchoscopic guidance in critically ill patients. *Arch Surg* 1996;131:129-132.
36. Reilly PM, Anderson HL, Sing RF, Schwab CW, Bartlett RH. Occult hypercarbia: an unrecognized phenomenon during percutaneous endoscopic tracheostomy. *Chest* 1995;107:1760-1763.
37. Masterton GR, Smurthwaite GJ. A complication of percutaneous tracheostomy. *Anaesthesia* 1994;49:452-453.
38. Kumar BN, Walsh RM, Courteney-Harris RG. Laryngeal foreign body: an unusual complication of percutaneous tracheostomy. *J Laryngol Otol* 1997;111:652-653.
39. Noden JB, Kirkpatrick T. Intrapleural percutaneous tracheostomy. *Anaesthesia* 1995;50:91.
40. Stoeckli SJ, Breitbach T, Schmid S. A clinical and histological comparison of percutaneous dilatational versus conventional surgical tracheostomy. *Laryngoscope* 1997;107:1643-1646.
41. Frosh A, Thomas ML, Weinbren J, Djazaeri B, Richards A. Tracheal ring rupture and herniation during percutaneous dilatational tracheostomy identified by fiberoptic bronchoscopy. *Rev Laryngol Otol Rhinol* 1997;118:179-180.
42. Teoh N, Parr MJ, Finfer SR. Bacteraemia following percutaneous dilatational tracheostomy. *Anaesth Intens Care* 1997;25:354-357.
43. Walz MK, Peitgen K, Thürauf N, et al. Percutaneous dilatational tracheostomy - early results and long-term outcome of 326 critically ill patients. *Intens Care Med* 1998;24:685-690.
44. Hill BB, Zweng TN, Maley RH, Charash WE, Toursarkissian B, Kearney PA. Percutaneous dilatational tracheostomy: report of 356 cases. *J Trauma* 1996;40:238-244.
45. Cobean R, Beals M, Moss C, Bredenberg CE. Percutaneous dilatational tracheostomy. A safe, cost-effective bedside procedure. *Arch Surg* 1996;131:265-271.
46. Whittet HB, Commins DJ, Waldmann CS. Skin tethering after dilatational percutaneous tracheostomy. *Anaesthesia* 1995;50:892-894.
47. Callanan V, Gillmore K, Field S, Beaumont A. The use of magnetic resonance imaging to assess tracheal stenosis following percutaneous dilatational tracheostomy. *J Laryngol Otol* 1997;111:953-957.
48. Charters P, Mannar R, Jones AS. Laryngotracheal stenosis after percutaneous tracheostomy. *Anaesthesia*



- 1994;49:825-826.
49. Bernard SA, Jones BM, Shearer WA. Percutaneous dilatational tracheostomy complicated by delayed life-threatening haemorrhage. *Aust N Z J Surg* 1992;62:152-153.
  50. Skowronski GA, Bersten AD, Vedig AE. Bleeding risk with percutaneous tracheostomy. *Intens Care Med* 1990;18:273.
  51. Friedman Y. Indications, timing, techniques, and complications of tracheostomy in the critically ill patient. *Current Opinion in Critical Care* 1996;2:47-53.
  52. Hazard P, Jones C, Benitone J. Comparative clinical trial of standard operative tracheostomy with percutaneous tracheostomy. *Crit Care Med* 1991;19:1018-1024.
  53. Holdgaard HO, Pedersen J, Jensen RH, et al. Percutaneous dilatational tracheostomy versus conventional surgical tracheostomy. A clinical randomised study. *Acta Anaesthesiol Scand* 1998;42:545-550.
  54. Smith I, Flemming S, Cernaianu A. Mishaps during transport from the intensive care unit. *Crit Care Med* 1990;18:278-281.
  55. Henrich DE, Blythe WR, Weissler MC, Pillsbury HC 3rd. Tracheostomy and the intensive care patient. *Laryngoscope* 1997;107:844-847.
  56. McHenry CR, Raeburn CD, Lange RL, Priebe PP. Percutaneous tracheostomy: a cost-effective alternative to standard open tracheostomy. *Am Surg* 1997;63:646-651.
  57. Friedman Y, Fildes J, Mizock B, et al. Comparison of percutaneous and surgical tracheostomies. *Chest* 1996;110:480-485.
  58. Graham JS, Mulloy RH, Sutherland FR, Rose S. Percutaneous versus open tracheostomy: a retrospective cohort outcome study. *J Trauma* 1996;42:245-248.
  59. Stauffer JL, Olson DE, Petty TL. Complications and consequences of endotracheal intubation and tracheostomy. A prospective study of 150 critically ill adult patients. *Am J Surg* 1981;70:65-76.
  60. Kirchner JA. Tracheotomy and its problems. *Surg Clin North Am* 1980;60:1093-1104.
  61. Nash M. Swallowing problems in the tracheotomized patient. *Otolaryngol Clin North Am* 1988;21:701-709.
  62. Bloss RS, Ward RE. Survival after tracheoinnominate artery fistula. *Am J Surg* 1980;139:251-253.