

## Case report

# Convulsions and Coma Associated with Iatrogenically Elevated CSF Calcium Levels Post Spinal Surgery: A Case Report

I. SMITH

*Department of Anaesthetics and Intensive Care, Palmerston North Hospital, Palmerston North, NEW ZEALAND*

---

### ABSTRACT

*Following elective revision of lumbar decompression and non-instrumented fusion, a 69 year old woman developed confusion, convulsions and coma associated with greatly elevated cerebrospinal fluid (CSF) calcium levels. It is presumed that the elevated calcium was secondary to the use of OsteoSet, a calcium sulfate pellet preparation used to augment autologous bone graft growth. (Critical Care and Resuscitation 2005; 7: 173-176)*

**Key words:** Lumbar decompression, complications, CSF calcium, seizures

---

### CASE REPORT

A 69-year old woman presented for elective revision of lumbar (L4/5) decompression and non-instrumented fusion for low back pain and spinal claudication. Her past medical history included rheumatoid arthritis, hypertension, cerebrovascular disease, peripheral vascular disease and rheumatic fever as a child. Her medications included aspirin, doxazosin, verapamil and piroxicam.

The surgical procedure included removal of old densely-adherent scar tissue adjacent to the dura. During this procedure, a dural tear was sustained and due to brisk epidural venous bleeding this could not be repaired and so was covered in absorbable gelatin foam (Gelfoam, Pharmacia and Upjohn Co., Puurs, Belgium). Denuding and exposure of periosteum was then performed. Osteoset (Wright Medical Technology Inc., Arlington, TN, USA) pellets were mixed with harvested bone and packed around the exposed posterolateral elements to provide non-instrumented fusion. Antibiotic prophylaxis was with a second generation cephalosporin and post-operative pain was managed with a patient controlled analgesia (PCA) system, using morphine.

A fever was noted on the second post-operative day and blood and urine cultures were performed. The patient was transfused with three units of packed red cells, as her haemoglobin was 82 g/L.

On the fifth post-operative day the patient was confused and complained of neck pain. Examination revealed hyper-reflexia and extensor plantar responses. All measured serum electrolytes and clinical observations were within normal limits. Later that night the patient's confusion increased and she became delirious, with hallucinations and generalised myoclonic twitching. Her blood pressure was elevated (200/110 mmHg) with new onset atrial fibrillation (AF) with a rapid ventricular response, which was treated with intravenous digoxin. An urgent computed tomography (CT) scan of the head was performed, with no abnormality seen. The patient was transferred to the intensive care unit (ICU) where, due to a deteriorating level of consciousness, (Glasgow Coma Score (GCS) = 7/15) and ongoing seizure activity she was sedated and her trachea was intubated.

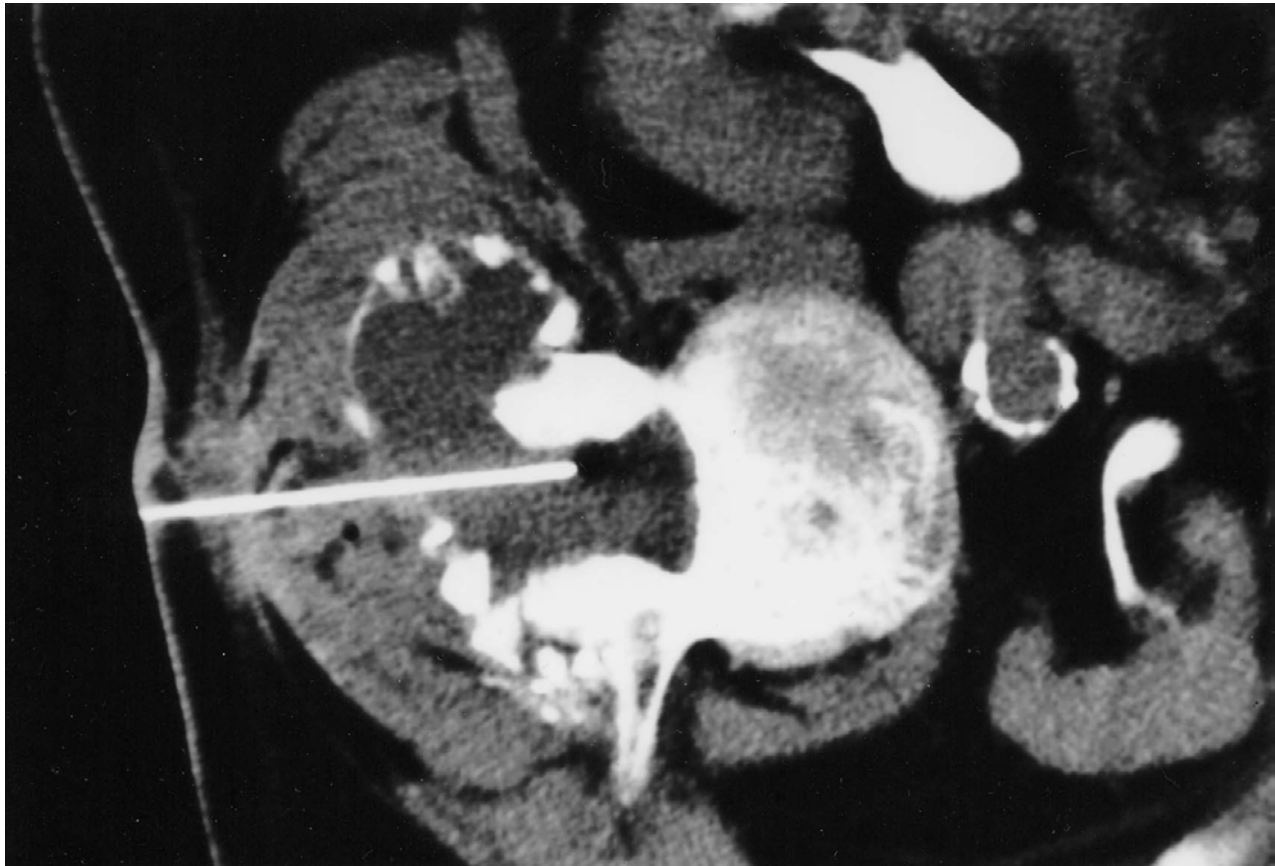
Intravenous amiodarone was commenced due to ongoing AF. Sedation was maintained with propofol. It was suspected at this stage that the patient had a basilar

---

*Correspondence to:* Dr I. Smith, Middlemore Hospital, Otahuhu, Auckland, New Zealand (e-mail: ismith007@clear.net.nz)

territory infarct, based on her clinical signs. A further CT scan of the head was performed, which was again within normal limits. The CT of the operative site showed an enlarged peridural collection containing

bone chips and a presumed cerebrospinal fluid (CSF) collection. This was aspirated under CT guidance as was the adjacent thecal sac CSF (see figure 1). Both aspirates appeared blood-stained and were sent



**Figure 1.** A CT image of the operative site demonstrating the peridural collection needle aspiration

**Table 1.** The CT guided aspiration results for the CSF-thecal sack, peridural sample and concurrent serum levels

| <i>Sample</i>        | <i>RBC<br/>x10<sup>6</sup>/L</i> | <i>WBC<br/>x10<sup>6</sup>/L</i>   | <i>Sodium<br/>mmol/L</i> | <i>Glucose<br/>mmol/L</i>      | <i>Calcium (total)<br/>mmol/L</i> |
|----------------------|----------------------------------|------------------------------------|--------------------------|--------------------------------|-----------------------------------|
| Peridural collection | 4490                             | 135<br>(80% segmented neutrophils) | 143                      | 6<br>(protein 5g/L)            | 7.45                              |
| CSF-thecal sack      | 2200                             | 132<br>(80% segmented neutrophils) | 135                      | 4.1<br>(protein not available) | 4.75                              |
| Serum                |                                  |                                    | 135                      | 7                              | 2.04 total<br>1.26 ionised        |

for microscopy and culture. CSF electrolytes were also measured by the o-cresolphthalein method (Roche Diagnostics, Auckland, NZ). Results are shown in table 1 above. Of note are the very high CSF calcium levels.

An electroencephalogram (EEG) showed continuous bilateral sharp slow wave complexes, consistent with encephalopathy. Serum electrolytes were normal throughout, no cultures grew pathogens and the CSF herpes simplex polymerase chain reaction (PCR) was negative. Despite these findings, the provisional diagnosis was infection and the patient was treated with acyclovir and broad-spectrum antibiotics.

Over the following few days sedation was weaned and the patient's condition steadily improved allowing extubation and discharge to the ward ten days post surgery. She was rehabilitated and discharged home with no residual deficit six weeks post admission.

## DISCUSSION

This is the first reported case of seizures and coma related to elevated CSF calcium from the use of a peridural calcium-rich osteoinductive matrix. In the absence of other causes, it is most likely that diffusion of calcium into the CSF caused the observed self-limiting neurological disturbance in this case.

OsteoSet is a pelletised form of crystalline calcium sulfate which is soluble in aqueous solution.<sup>1</sup> Over a 5 - 7 week period it dissolves with local inflammation and gradual ossification if implanted adjacent to periosteal tissue. Substantial literature supports its use to augment bone grafts in fusion, post curettage of benign bone lesions and non-union surgery.<sup>2</sup> Few complications have been noted and the manufacturer's contraindications include severe neurological disease, uncontrolled diabetes mellitus, severe degenerative bone disease, pregnancy, hypercalcaemia, renal disease and Pott's disease.<sup>1</sup> Animal studies have documented the safe placement of calcium sulfate in contact with the dura during spinal fusion surgery without complication.<sup>3</sup> Listed complications do not include seizures or coma, but self-limiting inflammatory local reactions are reported.<sup>4,5</sup> Product warnings make no mention of caution with CSF communication, hence use in this patient was consistent with the product recommendations.

The patient's presentation of decreasing level of consciousness and seizures (with EEG supporting a diagnosis of encephalopathy) was atypical with no immediately apparent cause. The elevated CSF calcium remains the only theoretical explanation for the observed clinical picture. Normal levels of CSF calcium are equivalent to serum ionised levels. This is usually 40 - 60% of total serum calcium.<sup>6</sup> In this case serum adjusted calcium was 2.37 mmol/L and ionised calcium

1.26 mmol/L. The expected CSF calcium would thus be around 1.3mmol/L rather than the observed 4.75 mmol/L. CSF protein is normally 0.2 - 0.4 g/L rising to 2 g/L in bacterial meningitis. Even marked protein elevation (5 g/L), as seen in this case, would be insufficient to bind enough calcium to significantly lower its levels. Calcium binding to albumin (approximately 60% of total protein, ~3 g/L), would account for a 0.1 mmol/L reduction in free ions. Hence free unionised calcium was likely to be very high in the CSF in this case, despite the elevated protein. Further studies in paediatric epileptics support the above ratios of calcium in serum and CSF (CSF calcium being equal to serum ionised or approximately 40 - 60% of serum total calcium).<sup>6</sup>

Studies of CSF calcium levels in various neuro-pathological conditions are limited. No naturally occurring or iatrogenically elevated CSF calcium levels of this degree have been previously documented. Less than 6% of non-seizing epileptics had elevated CSF calcium in a Scandinavian review.<sup>6</sup> The study group compared an epileptic population (312 patients) with a mixed neurological population (113 patients) finding no significant differences in CSF calcium levels. Research into the effects of elevated CSF calcium is scant and thus it is difficult to be sure just what levels are pathological. CSF calcium levels during a seizure remain unknown.<sup>7</sup> It is known though that increased levels of ionised calcium in brain tissue are associated with seizure activity and burst activity on EEG. Calcium flux is an important aspect of both NMDA and GABA receptor activity. This implies that calcium must be controlled within a tight range to prevent seizure potentials developing. In addition, increasing evidence exists showing some anticonvulsant medications act by antagonising calcium channels.<sup>8</sup>

It is presumed that the OsteoSet calcium sulfate dissolved in the peridural CSF collection and diffused into the CSF via the dural tear. Normal cephalad CSF bulk flow then led to status epilepticus and coma. The condition resolved with supportive treatment only. It is likely the dural leak sealed off due to local inflammation and wound healing, thus contributing to the self-limiting nature of the condition. Also the turnover of CSF, being in the region of 550 mL production (into a 150 mL volume) per day, would ultimately dilute the high calcium level. Had it not, reopening of the wound and removal of the pellets may have been required.

## CONCLUSION

High levels of CSF calcium produced iatrogenically are capable of profound changes in nerve transmission, consciousness and seizure induction as demonstrated by

this case. No cases exist in the literature of similar situations or such high levels of CSF calcium. This clinical situation arose from calcium diffusing from peridural areas into the CSF via the dural tear and then altering central nerve excitability. The use of dissolvable mineral substances adjacent to areas communicating with CSF should be avoided.

Received 9 December 04

Accepted 2 June 05

#### REFERENCES

1. Wright Medical Technologies, Inc. OsteoSet bone graft substitute. 1999. <http://www.wmt.com/biologics.htm>.
2. Moore W, Graves S, Bain G. Synthetic bone graft substitutes. *ANZ J Surg* 2001;71:354-361.
3. Turner T, Urban R, Gitelis S, Kuo K, Andersson G. Radiographic and histologic assessment of calcium sulfate in experimental animal models and clinical use as a resorbable bone-graft substitute, a bone-graft expander, and a method for local antibiotic delivery. *J. Bone and Joint Surg* 2001;83A, (suppl.2):8-18.
4. Robinson D, Alk D, Sandibank J, Farber R, Halperin N. Inflammatory Reactions Associated with a Calcium Sulfate Bone Substitute. *Ann of Transplant* 1999;4:91-97.
5. Lee GH, Khoury JG, Bell JE, Buckwalter JA. Adverse Reactions to Osteoset bone graft substitute, the incidence in a consecutive series. *Iowa Orthop J* 2002;22:35-38.
6. Plum C. Electrolyte variations in the cerebrospinal fluid in various pathological conditions. *Acta Psychiatr Neurol Scand* 1958;33:477-489.
7. Miyamoto Y, Yamamoto H, Murakami H, Kamiyama N, Fukuda M. Studies on cerebrospinal fluid ionised calcium and magnesium concentrations in convulsive children. *Paediatr Int* 2004;46:394-397.
8. Dichter MA, Brodie MJ. New Antiepileptic drugs. *N Eng J Med* 1996;334:1583-1590.