

# Cerebral fat embolism syndrome causing brain death after long-bone fractures and acetazolamide therapy

Criona M Walshe, James D Cooper,  
Thomas Kossmann, Ivan Hayes and Linda Iles

## Clinical record

A previously healthy, 19-year-old woman was admitted to the Alfred Hospital Trauma Centre after a motor vehicle accident. Her Glasgow Coma Score (GCS) at the scene was 14, decreasing to 11 when she developed upper airway obstruction requiring intubation. She was extricated from the vehicle and transferred to hospital by helicopter.

Computed tomography (CT) of the brain gave normal results. Her injuries included multiple facial fractures, fractures of the right femur and tibia, left medial malleolus, left superior and inferior pubic ramus, left wrist and left fourth metacarpal, pulmonary contusions and a grade IV splenic laceration.

Three hours after admission, the femoral and tibial fractures were stabilised with external fixation ("damage control" orthopaedic surgery), as her condition was too haemodynamically unstable for immediate definitive internal fixation. The pelvic fracture was stable. Definitive internal fixation of the femoral and tibial fractures, and open reduction and internal fixation of the left distal radius and left medial malleolus were delayed until Day 4. Ongoing haemorrhage required splenic embolisation both on the day of admission and again on Day 2. An inferior vena cava filter was inserted on Day 3.

An ophthalmologist who examined the patient's ocular injuries on Day 1 noted bilateral raised ocular pressure and recommended acetazolamide therapy. She received a bolus intravenous dose of acetazolamide (500 mg), followed by 250 mg intravenously 6-hourly. Ongoing raised ocular pressures on Day 2 led to a further bolus intravenous dose of acetazolamide (500 mg).

On Day 3, the patient developed metabolic acidosis with a normal anion gap. This was considered to be due to the acetazolamide. Figure 1A illustrates the arterial bicarbonate level over Days 1–7. The patient was at that time comfortably ventilating spontaneously with pressure support ventilation, requiring a fraction of inspired oxygen ( $F_{iO_2}$ ) of only 50%. Figure 1B shows the arterial partial pressure of carbon dioxide ( $P_{aCO_2}$ ) over Days 1–7. During Days 4–6, the metabolic acidosis increased, as indicated by a gradual decrease in serum bicarbonate concentration with appropriate hypocapnia, with associated hyperchloraemia caused by saline infusion (serum chloride concentration, 118–124 mmol/L). Her neurological state improved gradually to

## ABSTRACT

A 19-year-old woman with multiple fractures and mild brain injury developed severe cerebral fat embolism syndrome after "damage control" orthopaedic surgery.

Acetazolamide therapy to manage ocular trauma, in association with hyperchloraemia, caused a profound metabolic acidosis with appropriate compensatory hypocapnia. During ventilator weaning, unexpected brainstem coning followed increased sedation and brief normalisation of arterial carbon dioxide concentration. Autopsy found severe cerebral fat embolism and brain oedema.

In patients with multiple trauma, cerebral fat embolism syndrome is difficult to diagnose, and may be more common after delayed fixation of long-bone fractures. Acetazolamide should be used with caution, as sudden restoration of normocapnia during compensated metabolic acidosis in patients with raised intracranial pressure may precipitate coning.

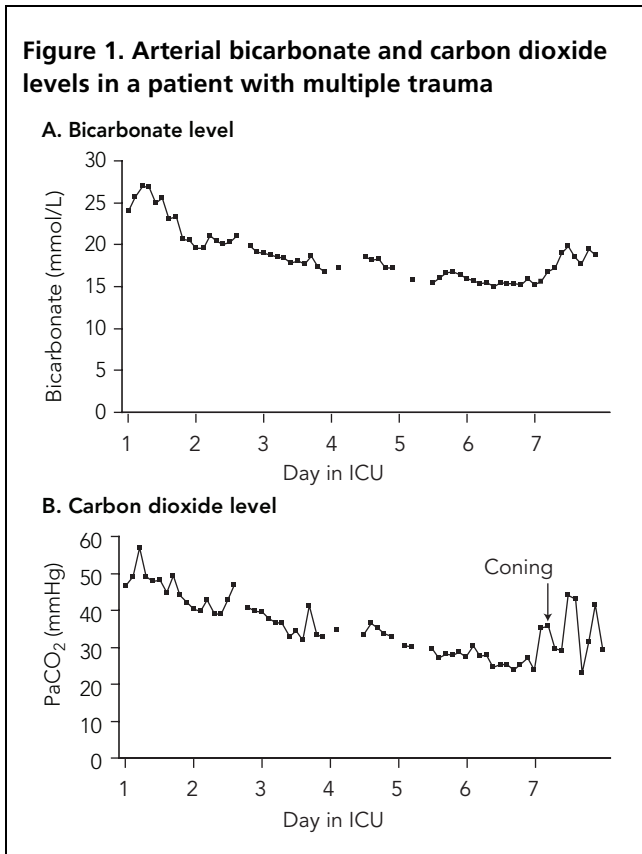
Crit Care Resusc 2007; 9: 184–186

bilateral flexion, which, in keeping with the initial GCS of 14, indicated that the primary brain injury was not severe.

At no time did the patient have other clinical or laboratory stigmata of fat embolism syndrome. Specifically, there were no petechial haemorrhages or thrombocytopenia, no fat globules noted on ophthalmological examination, and no electrocardiogram changes of right ventricular strain; the  $F_{iO_2}$  was 50%, and chest x-rays showed only mild non-specific changes.

On Day 6 in the ICU, during weaning from mechanical ventilation, the patient's neurological condition deteriorated. She became obtunded, with eye opening in response to pain and an extension motor response to painful stimuli. CT of the brain was requested, but was delayed and then was not performed. After midnight on Day 6, she became agitated, and propofol sedation was recommenced. However, the mechanical respiratory rate was not increased to maintain hyperventilation and pre-sedation hypocapnia ( $P_{aCO_2}$ , 24–27 mmHg). Five hours later,  $P_{aCO_2}$  was 35.3 mmHg, and arterial pH was 7.26. Thirty minutes later,

**Figure 1. Arterial bicarbonate and carbon dioxide levels in a patient with multiple trauma**



she developed extreme hypertension and tachycardia suggestive of brainstem herniation. Urgent CT of the brain found cerebral oedema, brainstem herniation and bilateral watershed infarcts. Her pupils became fixed and dilated. Angiogram carried out at 15:00 confirmed absent cerebral blood flow consistent with brain death. The following day, her liver, kidneys, heart and great vessels were harvested for organ donation. Transthoracic echocardiogram performed before organ retrieval did not demonstrate a patent foramen ovale.

At autopsy, the patient was found to have fat embolism syndrome, as evidenced by multiple fat emboli within the brain and lungs. Widespread cerebral oedema was considered to be due to fat embolism. The cause of death was fat embolism syndrome complicating multiple injuries sustained in a motor vehicle accident.

**Discussion**

Fat embolism syndrome is usually associated with long-bone or pelvic fractures, and more often with closed than with open fractures. Subclinical fat embolisation is probably common in trauma patients, and usually has no serious sequelae. The features of fat embolism syndrome typically become apparent 24–72 hours after initial injury, and 85%

of clinically apparent cases occur within 48 hours. Diagnosis is based on history in association with the classic triad of hypoxaemia, neurological abnormalities and a petechial rash, although frequently the clinical picture is incomplete. Diagnosis is usually difficult because of coexisting head injuries, pulmonary injuries or aspiration, and because the more specific tests for fat embolism syndrome are usually negative. The presence of tachycardia, tachypnoea and the absence of focal neurological symptoms and signs may sometimes distinguish fat embolism syndrome from head injury.<sup>1</sup>

Neurological manifestations of fat embolism syndrome include disorientation, confusion, stupor or coma. Global cerebral dysfunction is usual; however, focal neurological signs have been reported. In our patient, the diagnosis of cerebral fat embolism was complicated by a mild head injury together with the sedation required in the intensive care setting. Isolated cerebral fat embolism syndrome generally occurs in association with a normal brain CT result. However, there have been reports of fat embolism syndrome in association with CT evidence of cerebral oedema.<sup>2</sup> Magnetic resonance imaging is more sensitive, and demonstrates multiple small hyperintense intracerebral lesions, which may take days to develop.<sup>3</sup> Massive cerebral fat embolism has been associated with a patent foramen ovale.<sup>4</sup>

In patients with major trauma and long-bone fractures, fat may enter the bloodstream directly from the bone marrow. Fat globules are known to embolise systemically, even in the absence of a patent foramen ovale, by deforming and passing through the lungs, most commonly to the brain and kidneys. The pathophysiological effects are due to haemodynamic changes, impairment of pulmonary gas exchange and the direct effect of systemic fat embolisation to the brain and other tissues.<sup>1</sup> In our patient, fat embolism was likely to be due to a combination of the initial trauma, “damage control” orthopaedic surgery, and delayed internal fixation of the long bones.

Acetazolamide is a non-bacteriostatic sulfonamide. It inhibits carbonic anhydrase, the enzyme that catalyses a reversible reaction involving the hydration of carbon dioxide and the dehydration of carbonic acid. The diuretic action of acetazolamide is due to renal loss of bicarbonate ions which are involved in the reabsorption of sodium, water and potassium. There is resultant loss of sodium chloride and bicarbonate. The usual indication for acetazolamide in intensive care practice is to treat metabolic alkalosis. In the eye, acetazolamide decreases secretion of aqueous humour, resulting in decreased intraocular pressure. The metabolic acidosis associated with carbonic anhydrase inhibitors is usually mild. However, in our patient, large doses of acetazolamide used to manage raised intraocular pressure,

## CASE REPORTS

together with the hyperchloraemia from saline infusions, caused marked metabolic acidosis.

In our patient, the anion gap was normal. The bicarbonate concentration was 15–16 mmol/L (Figure 1A), and blood chloride concentration was 118–124 mmol/L. There was significant respiratory compensation with  $P_{aCO_2}$  of 24–27 mmHg (Figure 1B) and a normal pH for longer than 3 days.

The pH of brain extracellular fluid depends on brain  $P_{CO_2}$  and pH of cerebrospinal fluid (CSF). The electrolyte composition of the brain modifies slowly after changes in blood pH. Hypocapnia will acutely alkalinise the CSF but, over time, the pH of the CSF returns to normal. Carbon dioxide is lipid soluble and easily crosses the blood–brain barrier. Sudden normalisation of brain  $P_{CO_2}$  (as occurred in our patient) usually results in cerebral acidosis, vasodilation and raised intracranial pressure. In the setting of severe cerebral oedema caused by previously undiagnosed severe cerebral fat embolism, this was catastrophic and led to brainstem herniation and brain death.

Most patients with fat embolism syndrome recover fully, but it has a mortality usually cited as 5%–15%.<sup>5</sup> Our case highlights a catastrophic outcome which may occur after undiagnosed cerebral fat embolism in a patient with only mild traumatic brain injury. In trauma patients with a normal brain CT scan, depressed conscious state and orthopaedic injuries, fat embolism syndrome should always be considered. Damage control orthopaedic surgery involving the delay of definitive long-bone fixation until Days 3–6 after injury may also increase the incidence of serious fat embolism syndrome. Acetazolamide should be avoided if possible in patients with traumatic brain injury, because the resulting metabolic acidosis may be difficult to compensate

reliably, and unexpected normocapnia, particularly during weaning of mechanical ventilation, may precipitate coning in patients with raised intracranial pressure.

### Acknowledgements

We thank Dr Lindsay Worthley (Flinders Private Hospital, Adelaide, SA) for invaluable advice and discussion.

### Author details

**Criona M Walshe**, Intensive Care Registrar,<sup>1</sup> currently Mater Misericordiae Hospital, Dublin, Ireland

**James D Cooper**, Head of Trauma Intensive Care,<sup>1</sup> and Associate Director<sup>2</sup>

**Thomas Kossmann**, Professor and Director, Department of Trauma Surgery<sup>1</sup>

**Ivan Hayes**, Intensive Care Registrar<sup>1</sup>

**Linda Iles**, Forensic Pathologist<sup>3</sup>

<sup>1</sup> Alfred Hospital, Melbourne, VIC.

<sup>2</sup> National Trauma Research Institute, Melbourne, VIC.

<sup>3</sup> Victorian Institute of Forensic Medicine, Melbourne, VIC.

**Correspondence:** crionawalshe@hotmail.com

### References

- 1 Richards R. Fat embolism syndrome. *Can J Surg* 1997; 40: 334-9.
- 2 Meeke RI, Fitzpatrick GJ, Phelan DM. Cerebral oedema and the fat embolism syndrome. *Intensive Care Med* 1987; 13: 291-2.
- 3 Parizel PM, Demey HE, Veeckmans G, et al. Early diagnosis of cerebral fat embolism syndrome by diffusion-weighted MRI (Starfield Pattern). *Stroke* 2001; 32: 2942.
- 4 Ruiz-Gimeno JI, Ferre MA, Napal MT, Pelegrin F. [Prolonged coma due to fat embolism syndrome after fracture of the femur.] [Spanish]. *Rev Esp Anestesiol Reanim* 2006; 53: 187-90.
- 5 Mellor A, Soni N. Fat embolism. *Anaesthesia* 2001; 56: 145. □