

# A change of heart: acute cardiac dextroversion with cardiogenic shock after partial lung resection

Dharshi Karalapillai, Marco Larobina,  
Kushlani Stevenson and Laurie Doolan

## Clinical record

A 30-year-old man presented for radical lung resection to treat locally recurrent pleuropulmonary synovial sarcoma of the right lower lobe, with a solitary left lower lobe metastasis.

The patient initially presented 3 years previously with a solitary right middle lobe tumour. He underwent right middle lobectomy through a right posterolateral thoracotomy, which was complicated by postoperative haemorrhage requiring two further thoracotomies.

Subsequent computed tomography (CT) and positron emission tomography demonstrated disease recurrence locally in the right lobe and a solitary metastatic deposit in the apical segment of the left lower lobe. The right-sided disease impinged on the right main bronchus, pericardium and right atrium. Four cycles of neoadjuvant chemotherapy with ifosfamide and doxorubicin significantly reduced tumour size. As further imaging showed no systemic disease, surgery was potentially curative. The patient was an ex-smoker with no other significant past medical history. Preoperative appearance of a chest x-ray was consistent with his past history (Figure 1A).

## Surgery and anaesthesia

A right internal jugular central venous line and a left radial arterial pressure line were inserted, and general anaesthesia was induced in a routine fashion. Surgical access was achieved via a bilateral anterior thoracosternotomy "clam-shell" incision.

There were dense adhesions in the right pleural space. The right lower lobe tumour clearly involved the adjacent pericardium, and a single tumour nodule was present on the free wall of the right atrium. The solitary left lower lobe metastasis was wedge excised. The right lower lobe and anterior segment of the right upper lobe with adjacent pericardium were resected en bloc, necessitating removal of the entire lateral wall of the pericardium from the diaphragm to the right main pulmonary artery. The phrenic nerve was resected. The remainder of the right upper lobe was densely fixed to the chest wall with adhesions and could not be mobilised, leaving a large lower zone space. The tumour nodule on the right atrial free wall was excised separately without cardiopulmonary bypass. At the conclusion of the lung resection, bilateral apical and basal intercostal catheter drains were inserted

## ABSTRACT

Cardiac herniation and torsion are well described after intrapericardial pneumonectomy, but their occurrence after partial lung resection has been rarely discussed. This unusual case of acute right-sided cardiac dextroversion with torsion occurred in a 30-year-old man after radical right lower lobectomy, pericardial resection and a left lower-lobe wedge resection for locally recurrent and metastatic synovial sarcoma. We describe the management of this unusual cause of cardiogenic shock and review the current literature.

Cardiac herniation and torsion are an uncommon cause of cardiogenic shock after lung resection and, if diagnosed late, are associated with significant mortality.

Crit Care Resusc 2008; 10: 140–143

and placed on 20 cmH<sub>2</sub>O suction. The pericardium was left widely open.

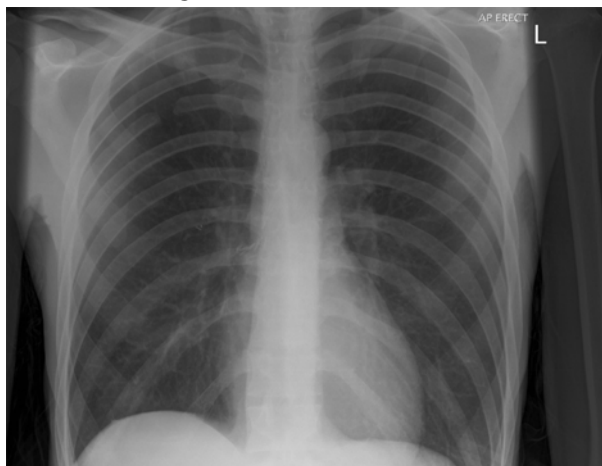
## Postoperative course

It was planned to admit the patient to the intensive care unit postoperatively. On transfer from the operating table, he developed acute haemodynamic compromise, with a rapid fall in systolic blood pressure to 60 mmHg. A 500 mL bolus of Gelofusine (B Braun Melsungen) was administered, and a noradrenaline infusion was begun. This corrected the hypotension sufficiently to allow the patient to be transferred intubated with intermittent positive pressure ventilation.

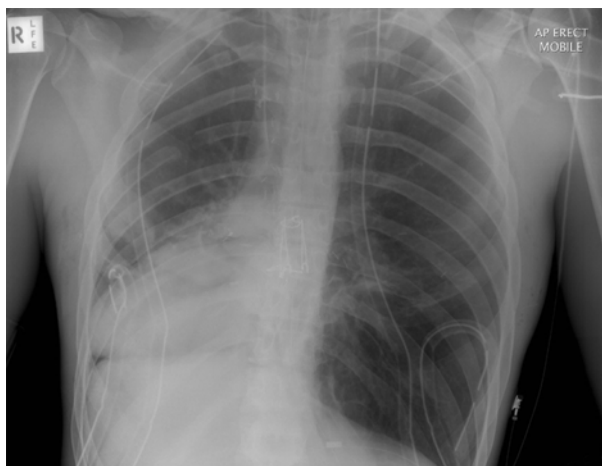On ICU admission, his oxygen saturation was 100% on Fio<sub>2</sub> of 1.0 and positive end-expiratory pressure of 5 cmH<sub>2</sub>O, heart rate was 100 bpm, and blood pressure was 120/60 mmHg on a noradrenaline dose of 6 µg/min. Central venous pressure measured via the internal jugular line was 26 mmHg. Both intercostal catheters were placed on 20 cmH<sub>2</sub>O suction.

Shortly thereafter, the patient rapidly became hypotensive as 120 mL blood drained from the right intercostal catheter. The haemoglobin concentration of an arterial sample taken for blood gas analysis was 78 g/L. As ongoing bleeding was suspected, he was given packed red cells (1

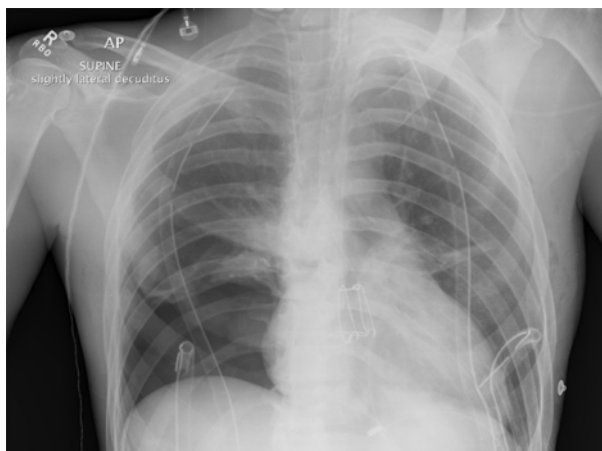
**Figure 1. Serial chest x-rays in a patient who underwent lung resection**



A. A preoperative chest x-ray showed the previous right middle lobectomy.



B. A postoperative chest x-ray on the patient's arrival in the intensive care unit showed evidence of acute cardiac herniation to the right with dextroversion.



C. A repeat x-ray after resumption of spontaneous ventilation and other treatment showed return of the cardiac silhouette to its normal position. The post-right lower lobectomy space is clearly apparent.

unit) and fresh frozen plasma (2 units). However, he became progressively more hypotensive (mean arterial blood pressure, 50 mmHg), with tachycardia (heart rate, 140 bpm) and a minimal response to a rapid escalation of the noradrenaline dose to 25 µg/min. Initial physical examination revealed gross deviation of the trachea to the right.

A chest x-ray was performed immediately and revealed a strikingly abnormal cardiac silhouette in the right chest, with the apex in the right costophrenic angle — compatible with cardiac dextroversion and torsion, an appearance resembling dextrocardia (Figure 1B).

The right and left intercostal catheters were immediately removed from suction, and the mean arterial blood pressure increased to 60 mmHg. However, tachycardia persisted (120 bpm), and central venous pressure increased further to 30 mmHg. A femoral central line was inserted; the central venous pressure measured via this route was only 10 mmHg. A repeat chest x-ray confirmed no change in the position of the cardiac silhouette.

A Pulsioath arterial transpulmonary thermodilution catheter (PULSIOCATH Medical Systems, Feldkirchen, Germany) was then inserted into the right femoral artery; the measured pressure correlated with the radial arterial pressure. The initial cardiac index was 3.0 L/min/m<sup>2</sup>.

As minimal improvement was seen clinically or on chest x-ray, the neuromuscular blockade was reversed, and the patient resumed spontaneous ventilation. He was positioned with the left side down. There was marked haemodynamic improvement, allowing the noradrenaline to be weaned off within minutes. Concurrently, the central venous pressure equalised at 6 mmHg via both the internal jugular and femoral routes. The head and neck cyanosis resolved, and the apex beat was palpated in the left fifth intercostal space in the mid-clavicular line. A repeat chest x-ray revealed that the cardiac silhouette had returned to the left mediastinum (Figure 1C).

All sedative agents were ceased, and the patient was maintained on a spontaneous ventilation mode. He was extubated uneventfully 16 hours later and required no further haemodynamic support.

About 30 hours later, the patient underwent reconstruction of the pericardial defect with a bovine pericardial patch. He remained in the ICU for 36 hours thereafter and was discharged from hospital 7 days later. Despite aggressive postoperative management with intercostal catheter suction, the right lower zone space persisted because of the fixity of the residual right upper lobe, with only a small rise in the right hemidiaphragm and continuing mediastinal shift.

### Discussion

Cardiac herniation with associated torsion occurs most commonly after intrapericardial pneumonectomy (first

## CASE REPORTS

reported by Bettman and Tenenbaum in 1948).<sup>1-11</sup> Pericardial defects resulting from trauma and congenital lesions can similarly result in cardiovascular compromise,<sup>12-16</sup> with an associated mortality of 50%–100%.<sup>17,18</sup> Pericardial herniation with complete cardiac dextroversion and cardiogenic shock after lobectomy is extremely rare.

The prerequisite for cardiac herniation and torsion is the combination of a pericardial defect and a space into which the heart can be displaced. A pericardial defect without an associated space rarely causes problems, as the heart is fixed in the middle mediastinum by the surrounding organs, principally the lungs. However, after pneumonectomy, the combination of a pericardial defect and a dramatic increase in intrathoracic pressure allow the heart to be displaced, most commonly into the pneumonectomy space. As the intrathoracic pressure during coughing can reach over 100 mmHg, displacement of the heart can occur even through a sutured pericardial defect.<sup>4</sup> Repositioning of the patient with the operative side down, positive pressure ventilation, rapid re-expansion of the remaining lung or suction placed on chest drains have all been described as contributing factors.<sup>14,19</sup> Rotation of the heart to the degree seen in our patient is uncommon after lobectomy, both because the pericardium is usually intact, and because there is insufficient residual space in the pleural cavity to allow cardiac displacement.

Our reported case was unusual as the pericardium was excised en bloc with the right lower lobe, and a large fixed pleural space remained because of the fixity of the upper lobe from previous adhesions. The combination of the pericardial defect, the potential space following lower lobectomy, suction on the chest drains, dependency of the operative side during transfer, and positive pressure ventilation led to acute cardiac dextroversion and cardiogenic shock.

The above factors can combine to cause cardiac herniation, which may occur to the right or left. It has been proposed that when the heart herniates to the right, its movement occurs with acute angulation and counterclockwise rotation, with the apex ultimately pointing towards the right posterior costophrenic sulcus, using the vena cavae as the fulcrum of rotation. This extensive rotation of the apex represents a true organo-axial volvulus or torsion of the heart with resultant dextroversion (base-to-apex axis points to the right).<sup>7</sup> In contrast, in left-sided herniation, the heart herniates without the same degree of rotation, and the normal leftward base-to-apex axis is preserved (laevocardia). In 1999, Kimura et al reviewed 68 cases of cardiac herniation after lung surgery.<sup>20</sup> They found that herniation occurred more commonly to the right than to the left, and was fatal in 12/46 right-sided herniations and torsions and 9/22 left-sided herniations.

Clinical features of cardiac herniation are non-specific, and diagnosis requires a high index of clinical suspicion. The

vast majority of cases occur intra-operatively — 75% when the patient is repositioned before the end of surgery. A large proportion of the remainder occur within the first 24 hours postoperatively.<sup>10</sup> Late herniation beyond 24 hours is rare, as adhesions form between the pericardium and the heart after this,<sup>21</sup> but cases have been reported up to 6 months postoperatively.<sup>11</sup>

The clinical presentation of cardiac herniation depends on the side to which it occurs, and falls into two broad categories: severe low output circulatory failure and acute superior vena cava syndrome. Severe chest pain is common in both right- and left-sided herniations. Cardiac torsion (also described as cardiac volvulus) is classically associated with right-sided herniations. Right-sided herniation and torsion are associated, as in our patient, with obstructive shock induced by kinking of the superior and inferior vena cavae, with subsequent dramatic reduction in cardiac preload. This results in hypotension, acutely elevated central venous pressure, tachycardia, and cyanosis of the head and neck unresponsive to supplemental oxygen therapy — the acute superior vena cavae syndrome.<sup>22</sup> In addition, heart sounds may be auscultated in the right side of the chest.<sup>11</sup> Many of these features were evident in our patient.

Left-sided herniation classically produces cardiac ischaemia and arrhythmias due to compression and strangulation of the ventricular wall by the open pericardial edges. If this is not rapidly relieved, myocardial infarction, hypotension due to cardiogenic shock and ventricular fibrillation may supervene. Previous reports have noted that myocardial infarction, if it occurs, is unlikely to be consistent with a coronary artery territory but rather corresponds to the area of myocardium directly strangulated by the pericardial defect.<sup>23</sup>

Electrocardiogram findings, like clinical presentation, are often non-specific and usually do not help diagnosis. Chest x-ray is the investigation of choice as its findings are characteristic, as recently reviewed by Mehanna et al.<sup>9</sup> For right-sided herniation and torsion, the cardiac silhouette is displaced from the midline, with the cardiac apex located in the right costophrenic angle (a radiological appearance similar to that seen in dextrocardia). An abnormal cardiac contour with a globular right heart border protruding into the right chest — the so-called “snow cone sign” — has also been described.<sup>8</sup> The latter is an important sign as it may be present before frank herniation and torsion. Other signs of right-sided cardiac herniation include the presence of a notch in the side of the cardiac vascular pedicle,<sup>22,24,25</sup> a kink in a central venous line at the level of the brachiocephalic venous junction,<sup>24</sup> a shift in the position of the chest tube and an empty pericardial sac. In addition, according to Nanda et al, a definitive diagnosis of cardiac herniation and torsion can be made if a pulmonary artery catheter is in situ.<sup>7</sup> With a pulmonary artery catheter, regardless of the site of insertion, the inferior loop of the

catheter in the right ventricle is always anticlockwise in a normal heart. A clockwise loop in the right ventricle is highly suggestive of cardiac volvulus.<sup>16</sup>

The radiological features of left-sided cardiac herniation may not be as striking. A hemispherical shape of the left cardiac border, notches between the great vessels and the herniated left chambers, a change in position of the chest drains and an empty pericardial sac have all been reported.<sup>9</sup>

The dramatic deterioration in the condition of a patient with cardiac herniation, with or without torsion, may preclude further investigations with CT or transthoracic or transoesophageal echocardiography. The first case of cardiac torsion diagnosed using echocardiography was described by Nanda et al.<sup>7</sup> Signs include the absence of the heart on left subcostal views and a "flipped heart" on right subcostal views. Short axis views confirm this rotation. Suprasternal views may reveal an abrupt truncation of the aorta and twisted head-end vessels. The superior and inferior vena cavae are dilated secondary to kinking produced by the volvulus.<sup>7</sup> However, it must be emphasised that practical considerations are likely to limit the usefulness of echocardiography.

The treatment of cardiac herniation, with or without torsion, is immediate thoracotomy and replacement of the heart to its normal position, and closure of the pericardial defect.<sup>4</sup> Temporising measures, which were effective in our patient, include cardiorespiratory support, a return to spontaneous ventilation if possible, avoidance of high inflation pressures in the remaining lung, positioning (with the operative side non-dependent) and removal of suction on the intercostal drain. Injection of air into the surgical hemithorax after pneumonectomy has also been successful.<sup>16</sup>

Surgery is required for definitive management. Various methods for closing the pericardial defect have been described. Since the 1970s, patch closure has often been used, with no documented cases of recurrence after this treatment. Patch material is most commonly glutaraldehyde-treated bovine pericardium. Autologous tissue, such as pleural flaps and fascial grafts, can be used but this is often limited by the amount of available tissue. Prosthetic materials, such as expanded polytetrafluoroethylene (ePTFE), can be used. Closing a significant defect by direct suture places undue tension on the remaining tissue and predisposes the repair to fail.<sup>4</sup>

In conclusion, we describe an unusual case of right-sided cardiac herniation with torsion after bilateral partial lung resection. Given that clinical signs are non-specific, and mortality is high without prompt recognition, a high index of suspicion is required in any patient who develops shock in the early postoperative period after lung resection, especially if the surgery has involved the creation of a pericardial defect.

## Author details

Dharshi Karalapillai, Registrar and Visiting Anaesthetist<sup>1,2</sup>

Marco Larobina, Registrar<sup>3</sup>

Kushlani Stevenson, Registrar<sup>1</sup>

Laurie Doolan, Staff Specialist<sup>1,2</sup>

1 Department of Intensive Care Medicine, Austin Hospital, Melbourne, VIC.

2 Department of Anaesthesia, Austin Hospital, Melbourne, VIC.

3 Department of Thoracic Surgery, Austin Hospital, Melbourne, VIC.

Correspondence: dharshikaralapillai@austin.org.au

## References

- 1 Vanovebeke HM, Schepens MA, Knaepen PJ. Acute cardiac herniation following intrapericardial pneumonectomy. *Acta Chir Belg* 1998; 98: 98-100.
- 2 Kiev J, Parker M, Zhao X, Kasirajan V. Cardiac herniation after intrapericardial pneumonectomy and subsequent cardiac tamponade. *Am Surg* 2007; 73: 906-8.
- 3 Dippel WF, Ehrenhaft JL. Herniation of the heart after pneumonectomy. *J Thorac Cardiovasc Surg* 1973; 65: 207-9.
- 4 Shimizu J, Ishida Y, Hirano Y, et al. Cardiac herniation following intrapericardial pneumonectomy with partial pericardiectomy for advanced lung cancer. *Ann Thorac Cardiovasc Surg* 2003; 9: 68-72.
- 5 Montero CA, Gimferrer JM, Fita G, et al. *Chest* 2000; 117: 1184-5.
- 6 Ohri SK, Siddiqui AA, Townsend E. Cardiac torsion after lobectomy. *Ann Thorac Surg* 1992; 53: 703-5.
- 7 Nanda S, Pamula J, Bhatt SP, et al. Cardiac herniation and volvulus with acquired dextrocardia: echocardiographic diagnosis. *Echocardiography* 2007; 24: 870-4.
- 8 Gurney JW, Arnold S, Goodman LR. Impending cardiac herniation: the snow cone sign. *Radiology* 1986; 161: 653-5.
- 9 Mehanna MJ, Israel GM, Katigbak M, Rubinowitz AN. Cardiac herniation after right pneumonectomy. *J Thorac Imaging* 2007; 22: 280-2.
- 10 Baaijens PF, Hasenbos MA, Lacquet LK, Dekhuijzen PN. Cardiac herniation after pneumonectomy. *Acta Anaesthesiol Scand* 1992; 36: 842-5.
- 11 Zandberg FT, Verbeke SJ, Snijder RJ, et al. Sudden cardiac herniation 6 months after right pneumonectomy. *Ann Thorac Surg* 2004; 78: 1095-7.
- 12 Onem G, Baltalarli A, Sungurtekin H, et al. Iatrogenic cardiac herniation and torsion after surgery for a penetrating cardiac injury. *Tex Heart Inst J* 2006; 33: 526-8.
- 13 Kermond AJ. The dislocated heart: an unusual complication of major chest injury. *Radiology* 1976; 119: 59-60.
- 14 Kerins M, Maguire E, Lacy C. Cardiac luxation: an unusual complication of a log roll. *Emerg Med J* 2005; 22: 913-5.
- 15 Furusawa T, Fukaya Y, Amano J. Herniation of the heart due to traumatic rupture of the pericardium. *Eur J Cardiothorac Surg* 2000; 17: 752-3.
- 16 Brogdon BG, Georgy BA. An unusual twist. *Br J Radiol* 1998; 71: 691-2.
- 17 Veronisi G, Spaggiari L, Solli PG, et al. Cardiac dislocation after extended pneumonectomy with pericardioplasty. *Eur J Cardiothorac Surg* 2001; 19: 89-91.
- 18 Rodenwaldt J, Lembcke A, Wiese T, et al. Postoperative dislocation of the heart after pneumonectomy. *Circulation* 2002; 105: e49-50.
- 19 Self RJ, Vaughan RS. Acute cardiac herniation after radical pleuropneumonectomy. *Anaesthesia* 1999; 54: 564-6.
- 20 Kimura T, Chiba Y, Ihaya A, et al. A case of acute right coronary occlusion with cardiac herniation following right pneumonectomy. *J Jpn Assoc Chest Surg* 1999; 13: 660-4.
- 21 Dieraniya AK. Cardiac herniation following intrapericardial pneumonectomy. *Thorax* 1974; 29: 545-52.
- 22 Arndt RD, Frank CG, Schmitz AL, Haveson SB. Cardiac herniation with volvulus. *AJR Am J Roentgenol* 1978; 130: 155-6.
- 23 Ohshima H, Takeuchi H, Yamaguchi T, et al. Late cardiac strangulation due to an iatrogenic pericardial defect. *Chest* 1993; 104: 977-8.
- 24 Brady MB, Brogdon BG. Cardiac herniation and volvulus: radiographic findings. *Radiology* 1986; 161: 657-8.
- 25 Castillo M, Oldham S. Cardiac volvulus: plain film recognition of an often fatal condition. *AJR* 1985; 145: 271-2. □