

Echocardiography is the best cardiovascular “monitor” in septic shock

Andrew K Hilton

Haemodynamic instability and respiratory failure are common in critically ill patients, with sepsis being a frequent cause. Echocardiography is a very useful, practical and safe bedside tool for the diagnosis and management of these problems. It provides real-time two-dimensional structural and functional imaging of the heart and vascular system. In combination with Doppler ultrasound techniques, it provides blood and tissue velocity information from which can be derived haemodynamic data equivalent to those provided by conventional invasive haemodynamic monitoring.

Echocardiography should be considered the first-line monitoring and diagnostic tool in the management of patients with sepsis as it can:

- confirm the diagnosis functionally and possibly indicate its specific source (eg, endocarditis or pericarditis);
- rapidly exclude or include important differential diagnoses (eg, tamponade and pulmonary embolism);
- guide intensive care unit interventions, such as intravascular volume expansion, choice of vasopressors or inotropes, and ventilatory support, especially with respect to its possible impact on right ventricular function; and
- indicate whether conventional invasive haemodynamic monitoring is required and, if so, enable “calibration” of the haemodynamic data thus obtained with the direct structural and functional information provided by echocardiography.

In this scheme, echocardiography is conducted before invasive haemodynamic monitoring in the management of sepsis in the ICU (Figure 1).

Echocardiography and the critically ill

The first reports directly addressing the use of transthoracic echocardiography (TTE) in the ICU were published in 1985 and included an investigation of myocardial dysfunction in septic shock.^{1,2} Although the clinical utility of echocardiography was apparent, imaging quality was reduced by technological limitations in at least a third of ventilated ICU patients. More interest in the use of echocardiography in the ICU followed the general clinical introduction of transoesophageal echocardiography (TOE) in the late 1980s. At that time, TOE had unquestionably better imaging ability in ventilated patients than TTE. Furthermore, it had unmatched clinical utility in the ICU management of cardiac surgical patients, and in the diagnosis of specific problems,

ABSTRACT

Haemodynamic instability and respiratory failure are common in critically ill patients, with sepsis being a frequent cause. Echocardiography is a useful, practical and safe bedside tool for diagnosis and management of these problems. It provides real-time two-dimensional structural and functional imaging of the heart and vascular system. With Doppler techniques, it provides blood and tissue velocity information from which to derive haemodynamic data equivalent to those provided by conventional invasive haemodynamic monitoring. Its use can help determine whether, and when, continuous haemodynamic monitoring should be instituted. It is the best monitor for the management of sepsis because of its broad clinical utility and as a reference for the judicious use of invasive monitoring.

Crit Care Resusc 2006; 8: 247–251

such as prosthetic valvular dysfunction, endocarditis and thoracic aortic dissection.

Advances in ultrasound technology have narrowed the gap between the imaging quality obtained by TOE and TTE in the ventilated critically ill patient. TTE can now be considered the echocardiographic modality of first choice for imaging in most ICU patients, including those with sepsis, as the image quality and structural and functional information obtained is usually sufficient for initial evaluation.³ Importantly, TTE avoids the serious, albeit uncommon, complications of TOE (eg, oesophageal and gastric perforation and haemorrhage), and can be set up and performed in a third of the time or less. TOE should be reserved for patients for whom TTE image quality is insufficient to answer the relevant clinical question(s), and for specific indications, such as complex cardiac structural and valvular abnormalities (eg, endocarditis, prosthetic valve dysfunction and congenital abnormalities), or thoracic aortic pathology (eg, aortic root abscess and acute dissection).

Recent studies show that consultant intensivists can be taught to perform echocardiography safely and accurately on ICU patients.^{4,5} The success of these ICU echocardiography programs was predicated on a supportive and cooperative relationship with cardiologist echocardiographers, and a consultant intensivist cohort willing to invest substantial

POINTS OF VIEW

time (6–12 months) to become proficient. While no specific ICU-based echocardiography programs for trainee intensivists have been described in Australia, the United Kingdom or the United States, they are deemed important training in many European ICUs.

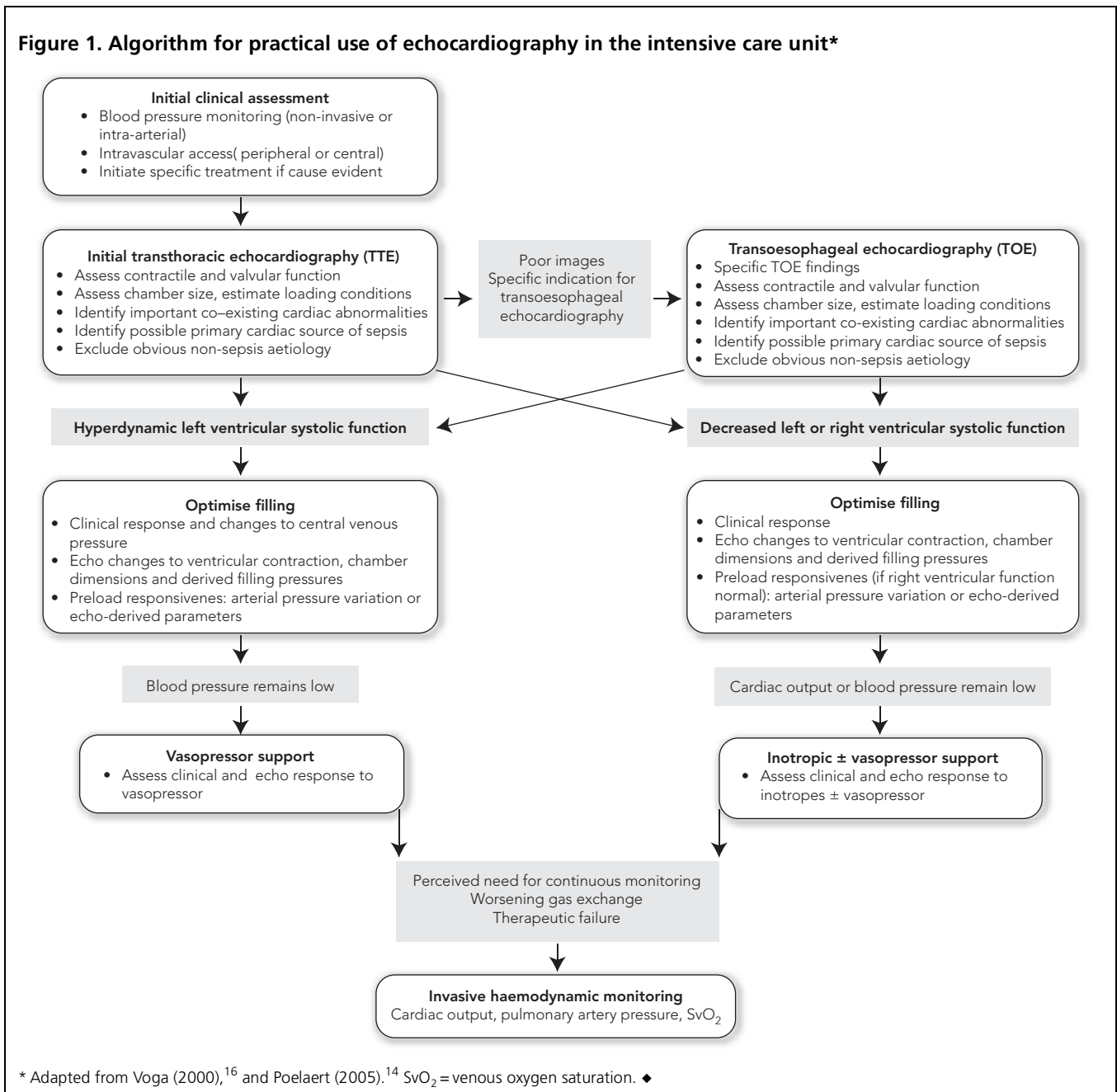
Clinical utility of echocardiography in the ICU

A surveillance echocardiography study revealed that a significant proportion of patients admitted to the ICU with non-cardiac illnesses have underlying cardiac abnormalities.⁶ Furthermore, it appears that an echocardiographic

examination is more likely to change the management of critically ill patients compared with other in-hospital patient groups.⁷ Similarly, when the indicated use of echocardiography is retrospectively examined in critically ill patients, there is overwhelming evidence to support its ability to provide diagnostic information and to guide or change management.^{5,8} However, there are no prospective studies that provide outcome data following the use of echocardiography in the ICU.

It is obvious that echocardiography can be useful in the management of patients with sepsis. In patients who present with haemodynamic instability or hypoxia,

Figure 1. Algorithm for practical use of echocardiography in the intensive care unit*



POINTS OF VIEW

Table 1. Commonly used echo-derived haemodynamic parameters (for details see references^{11,13-16})

Parameter	Echo modality	Echo measurement
Cardiac output	2-dimensional	Stroke volume from estimated difference between left ventricle systolic and diastolic volumes
	Pulse wave Doppler	Product of the integrated systolic left ventricular outflow tract flow velocity/time envelope, and measured area of left ventricular outflow tract
Central venous pressure	2-dimensional	Cyclic changes in diameter of inferior vena cava (spontaneous respiration)
Left atrial pressure	2-dimensional	Position and movement of interatrial septum (especially if right atrial pressure known)
	Pulse wave Doppler	Mitral inflow velocities Pulmonary venous flow velocities
	Tissue Doppler	E/Ea ratio > 7, pulmonary artery wedge pressure > 15 mmHg.
Systolic pulmonary artery pressure	Continuous wave Doppler	Peak tricuspid regurgitation pressure gradient (plus right atrial pressure)
Preload dependence	2-dimensional	Respiratory variation of diameter of superior vena cava (collapsibility index > 36% indicates responsiveness) Respiratory variation of diameter of inferior vena cava
	Pulse wave Doppler	Respiratory variation in aortic flow velocity
Left ventricle contractile function	2-dimensional	Qualitative Ejection fraction or fractional area change (directly measured or calculated)
	Continuous wave Doppler	dP/dt (if mitral regurgitation jet present)
	Tissue Doppler	Peak S wave velocity at mitral annulus
Right ventricle contractile function	2-dimensional	Qualitative
	Continuous wave Doppler	dP/dt (if tricuspid regurgitation jet present)
	Tissue Doppler	Peak S wave velocity at tricuspid annulus

E/Ea ratio = ratio of pulse wave Doppler E wave to tissue Doppler Ea wave. dP/dt = rate of left ventricular pressure rise with respect to time. ◆

echocardiography can help determine whether the underlying problem is sepsis, and provide or support alternative diagnoses, such as primary cardiac disease, pericardial disorders, pulmonary embolism and aortic dissection.^{8,9} Furthermore, echocardiography studies in patients with sepsis demonstrate that various haemodynamic indices, such as cardiac output, left atrial pressure and pulmonary systolic pressure, can be reliably determined.^{10,11} At times, echocardiography may provide a more accurate value for cardiac output than thermodilution, particularly in the presence of tricuspid regurgitation or intracardiac shunts.¹² However, there is no prospective evidence that echocardiography-driven management of patients with sepsis leads to better outcomes.

Haemodynamic data

It is possible and often relatively easy to derive or estimate standard haemodynamic data using both two-dimensional and Doppler echocardiography¹³⁻¹⁵ (Table 1). Although the information obtained is not continuous, repeating a TTE study is relatively easy as long as an experienced operator

is available. Patients with ongoing or extreme cardiovascular instability necessitating frequent clinical intervention may require continuous monitoring, which is provided by invasive haemodynamic monitoring. However, the need for this intervention reasonably follows initial echocardiographic evaluation and assessment of patients' response to treatment.

More importantly, echocardiography may allow the data obtained with haemodynamic monitoring to be contextualised or calibrated to the direct echocardiographic visualisation of cardiac structure and function, and provide incremental diagnostic information. Examples include the interpretation of a high reading of central venous pressure or pulmonary artery wedge pressure when tricuspid or mitral regurgitation, respectively, are demonstrated on echocardiography; or the interpretation of identical filling pressures in the presence or absence of ventricular dysfunction.

Also, echocardiography in combination with minimal invasive haemodynamic monitoring can more accurately derive more complex haemodynamic data. A simple example follows from the direct measurement of right atrial

pressure with a central venous line. The position of the mobile interatrial septum at any one time is determined by the pressure gradient between the right and left atria. Fixed positioning of the interatrial septum to the left or right indicates left atrial pressures that are either significantly lower or higher, respectively, than the measured right atrial pressure. Oscillation of the interatrial septum from one side to the other is evidence for right and left atrial pressures that approximate each other.

A more complex example is that of patients with pulmonary hypertension, who almost invariably have tricuspid regurgitation. Directly measured right atrial pressure can be simply added to the echocardiographically determined peak TR pressure gradient to determine the peak right ventricular systolic pressure, and thus systolic pulmonary arterial pressure (assuming no systolic obstruction at or near the pulmonary valve).

No haemodynamic monitoring, with the possible exception of monitoring of mixed venous saturation, has been found to improve patient outcome in sepsis. Thus, it should not be demanded or expected that echocardiographically derived values duplicating traditional haemodynamic indices will necessarily affect outcome in sepsis. However, echocardiography does allow the rapid qualitative and semi-quantitative assessment of the patient with sepsis and provides an instant guide to management. The need for continuous invasive haemodynamic monitoring may be indicated by this initial or subsequent assessment. In the patient with sepsis whose condition is complex or unstable, the combination of echocardiography and invasive monitoring appears a powerful tool.

Management of sepsis

Manipulation of intravascular volume

If blood pressure or cardiac output is low, then a frequent first step in cardiovascular support is to optimise intravascular volume to maximise cardiac output. Echocardiography can be used to estimate right- and left-sided filling pressures, to assess ventricular function, and thus to guide fluid therapy. If there is uncertainty as to the need for volume therapy, dynamic measures, such as preload responsiveness, may be more used.¹⁷ In mechanically ventilated patients, this preload responsiveness is reflected in increased respiratory variation in systemic blood pressure. This is demonstrated echocardiographically by increased respiration-induced phasic changes to left ventricular outflow tract velocities or vena cava diameter.¹⁸⁻²⁰ Simplistically, positive pressure ventilation alters systemic cardiac output through inspiratory changes to right ventricular output.¹⁵ Preload responsiveness depends on right ventricular function — a failing right ventricle shows marked variability in output

irrespective of preload, because of its increased sensitivity to the imposed phasic afterloading effects of positive pressure ventilation. In contrast, a normal right ventricle shows phasic inspiratory diminution of stroke volume, secondary to a transient decrease in venous return and right ventricle preload. This is exacerbated by relative hypovolaemia and properly represents preload responsiveness. Although phasic changes in blood pressure may be as good a measure of preload responsiveness as echocardiographic measurements, they may be better interpreted and more useful as a guide to volume therapy after echocardiographic evaluation of right ventricular function.

Choice of vasopressors and inotropes

In patients with sepsis and hypotension, echocardiographic assessment can very quickly guide the choice between vasopressor support (normal or hyperdynamic ventricular function), inotropic support (ventricular dysfunction), or both. The use of inotropes in patients with hyperdynamic left ventricular contraction who require vasopressor support alone can occasionally cause dynamic left ventricular outflow obstruction, especially if significant left ventricular hypertrophy is present.¹⁵ This may result in rapid haemodynamic deterioration, the cause of which is unlikely to be evident with invasive haemodynamic monitoring, but is easily demonstrated with echocardiography.

Neither can it be assumed that patients with sepsis require vasopressors only. There may be pre-existing structural or functional heart disease that necessitates the use of inotropes. Furthermore, the phenomenon of septic myocardial dysfunction is well recognised and occurs in at least 25% of critically ill patients,^{21,22} but may not be clinically apparent in young, previously well patients. Echocardiography can alert the physician to its presence and severity, and also detect changes to contractile function during the course of acute illness. This will also facilitate the interpretation of other haemodynamic data and further guide management.

Choice of inotropic therapy can be directly guided by noting individual response to different inotropes. This may be particularly important when non-adrenergic inotropes, such as phosphodiesterase III inhibitors (eg, milrinone) or calcium sensitisers (eg, levosimendan) are being considered.²³ Echocardiographically demonstrated failure of conventional inotropic therapy is more likely to embolden the ICU physician to consider these less familiar, but possibly very efficacious, alternatives.

Ventilatory support

Respiratory failure is often associated with sepsis, either because of the direct effects of pulmonary sepsis or the

POINTS OF VIEW

systemic response to sepsis with the onset of acute lung injury. Pre-existing cardiorespiratory disease may also contribute. In these circumstances, mechanical ventilatory support is required, often with high levels of positive end-expiratory pressure. Intermittent positive pressure ventilation can impose an acute impedance to right ventricle ejection, on top of any pre-existing or sepsis-induced pulmonary hypertension or right ventricular systolic dysfunction.²⁴ Echocardiography allows the direct assessment of right ventricular function and measurement of systolic pulmonary artery pressure. Therefore, it can be used to monitor the effects of intermittent positive pressure ventilation, especially changes to tidal volume and positive end-expiratory pressure.

Conclusions

Improvements in ultrasound technology have made echocardiography, especially TTE, a practical and safe tool for the diagnosis, haemodynamic characterisation and management of patients with sepsis. Its use can help to determine whether, and when, continuous haemodynamic monitoring should be instituted. Echocardiography is the best monitor for the management of sepsis because of its broad clinical utility, as well as a reference for the judicious use of invasive monitoring.

Author details

Andrew K Hilton, Intensive Care Specialist
The Alfred Hospital, Melbourne, VIC.

Correspondence: A.Hilton@alfred.org.au

References

- 1 Mellow E, Parker MM, Cunnion RE, et al. Usefulness of two-dimensional echocardiography to follow reversible myocardial dysfunction in humans with septic shock [abstract]. *Clin Res* 1985; 33: 294A.
- 2 Parker MM, Cunnion RE, Parrillo JE. Echocardiography and nuclear cardiac imaging in the critical care unit. *JAMA* 1985; 254: 2935-9.
- 3 Joseph MX, Disney PJS, Da Costa R, et al. Transthoracic echocardiography to identify or exclude cardiac cause of shock. *Chest* 2004; 126: 1592-7.
- 4 Benjamin E, Griffin K, Leibowitz AB, et al. Goal-directed transesophageal echocardiography performed by intensivists to assess left ventricular function: comparison with pulmonary artery catheterization. *J Cardiothorac Vasc Anesth* 1998; 12: 10-5.
- 5 Colreavy FB, Donovan K, Lee KY, et al. Transesophageal echocardiography in critically ill patients. *Crit Care Med* 2002; 30: 989-96.
- 6 Bossone E, Di Giovine B, Watts S, et al. Range and prevalence of cardiac abnormalities in patients hospitalized in a medical intensive care unit. *Chest* 2002; 122: 1370-6.
- 7 Tam JW, Nichol J, MacDiarmid AL, et al. What is the real clinical utility of echocardiography? A prospective observational study. *J Am Soc Echocardiogr* 1999; 12: 689-97.
- 8 Slama MA, Novara A, van de Putte P, et al. Diagnostic and therapeutic implications of transesophageal echocardiography in medical intensive care unit patients with unexplained shock, hypoxemia, or suspected endocarditis. *Intensive Care Med* 1996; 22: 916-22.
- 9 Jones AE, Craddock PA, Tayal VS, et al. Diagnostic accuracy of left ventricular function for identifying sepsis among emergency department patients with non-traumatic symptomatic undifferentiated hypotension. *Shock* 2005; 24: 513-7.
- 10 Bousuges A, Blanc P, Molenat F, et al. Evaluation of left ventricular filling pressure by transthoracic Doppler echocardiography in the intensive care unit. *Crit Care Med* 2002; 30: 362-7.
- 11 Vieillard-Baron A, Prin S, Chergui K, et al. Hemodynamic instability in sepsis. Bedside assessment by Doppler echocardiography. *Am J Respir Crit Care Med* 2003; 168: 1270-6.
- 12 Balik M, Pachel J, Hendl J. Effect of the degree of tricuspid regurgitation on cardiac output measurements by thermodilution. *Intensive Care Med* 2002; 28: 1117-21.
- 13 Brown JM. Use of echocardiography for hemodynamic monitoring. *Crit Care Med* 2002; 30: 1361-4.
- 14 Poelaert JI, Schupfer G. Hemodynamic monitoring utilising transesophageal echocardiography. The relationships among pressure, flow, and function. *Chest* 2005; 127: 379-90.
- 15 Vignon P. Hemodynamic assessment of critically ill patients using echocardiography Doppler. *Curr Opin Crit Care* 2005; 11: 227-34.
- 16 Voga G, Krivec B. Echocardiography in the intensive care unit. *Curr Opin Crit Care* 2000; 6: 207-13.
- 17 Pinsky MR. Assessment of indices of preload and volume responsiveness. *Curr Opin Crit Care* 2005; 11: 235-9.
- 18 Feissel M, Badie J, Merlani PG, et al. Pre-ejection period variations predict the fluid responsiveness of septic ventilated patients. *Crit Care Med* 2005; 33: 2534-9.
- 19 Feissel M, Michard F, Faller JP, et al. The respiratory variation in inferior vena cava diameter as a guide to fluid therapy. *Intensive Care Med* 2004; 30: 1834-7.
- 20 Vignon P. Evaluation of fluid responsiveness in ventilated septic patients: back to venous return. *Intensive Care Med* 2004; 30: 1699-701.
- 21 Bailén MR, de Hoyos EA, Martínez AL, et al. Reversible myocardial dysfunction, a possible complication in critically ill patients without heart disease. *J Crit Care* 2003; 18: 246-52.
- 22 Mehta NJ, Khan IA, Gupta V, et al. Cardiac troponin I predicts myocardial dysfunction and adverse outcome in septic shock. *Int J Cardiol* 2004; 95: 13-7.
- 23 Morelli A, De Castro S, Teboul JL, et al. Effects of levosimendan on systemic and regional hemodynamics in septic myocardial depression. *Intensive Care Med* 2005; 31: 638-44.
- 24 Vieillard-Baron A, Schmitt JM, Augarde R, et al. Acute cor pulmonale in acute respiratory distress syndrome submitted to protective ventilation: incidence, clinical implications, and prognosis. *Crit Care Med* 2001; 29: 1551-5. □