

Extracorporeal membrane oxygenation for critically ill patients with influenza A (H1N1) 2009: a case series

Clodagh A M Power, P Vernon van Heerden,
David Moxon, Graham Martindale and Brigit Roberts

As of March 2010, the influenza A (H1N1) 2009 virus remains the world's dominant circulating influenza strain.¹ The United States, Canada, Mexico, Europe, Australia and New Zealand can each claim a large burden in terms of the pressures placed by the H1N1 virus on social, medical and economic resources. Patients at the most severe end of the clinical spectrum may require protracted intensive care unit admission for mechanical ventilation, acute respiratory distress syndrome rescue therapies and, in refractory cases, extracorporeal membrane oxygenation (ECMO).

Over the period July–December 2009, five patients in the ICU of Sir Charles Gairdner Hospital (SCGH) in Perth, Western Australia, received ECMO as part of their treatment for severe pneumonitis due to infection with influenza A (H1N1). ECMO was only considered in patients for whom all conventional modalities of treatment available to us for acute lung injury had been exhausted (Table 1).

Before this, ECMO had rarely been undertaken in our department (about one to two cases per year), and then usually for cardiac indications (venoarterial ECMO). The use of ECMO for prolonged periods for a respiratory indication (severe hypoxaemia due to acute lung injury) was therefore relatively novel, and represented a challenge in terms of allocation of resources and personnel. Access cannulae were placed in all instances by cardiothoracic surgeons. Critical care pathways were developed ad hoc as the H1N1 epidemic evolved, with reference to pathways from more experienced ECMO centres.

Clinical records

Patient 1

A 33-year-old man presented with a 7-day history of cough, fevers, anorexia and progressive shortness of breath and 3 days of haemoptysis. Despite a course of antibiotics, he had continued to deteriorate. He was a non-smoker and was undergoing lifestyle modification for the management of hypertension and obesity.

On admission, he was noted to have bilateral crepitations and an expiratory wheeze, an arterial oxygen saturation (SpO₂) of 87% on room air and a temperature of over 39°C. A chest x-ray (CXR) showed bilateral opacities. He was commenced on antibiotics and later on non-invasive

ABSTRACT

In this case series, we report on five patients with influenza A (H1N1) who received extracorporeal membrane oxygenation (ECMO) treatment between July and December 2009 in the intensive care unit of Sir Charles Gairdner Hospital in Perth, Western Australia. In considering these cases, we highlight the indications, risks and potential benefits associated with ECMO, whose role remains, as yet, largely undefined in the setting of H1N1 critical illness.

Crit Care Resusc 2011; 13: 38–43

bilevel positive airway pressure (BiPAP) because of increasing work of breathing.

A computed tomography pulmonary angiogram ruled out a pulmonary embolus as the cause of his worsening condition, but demonstrated extensive alveolar infiltration.

He was admitted to the ICU after 3 days for intubation and ventilatory support in the setting of respiratory exhaustion. Oseltamivir (75 mg twice daily), steroids and nebulised prostacyclin were added to his medications and he was nursed in a semi-prone position and actively cooled.

Venoarterial ECMO was introduced on Day 2 of the patient's ICU stay because his arterial partial pressure of oxygen (PaO₂) was persistently less than 50 mmHg (6.7 kPa) despite inverse-ratio ventilation and a fraction of inspired oxygen (FiO₂) of 1.0. H1N1 infection was confirmed on Day 3 of his ICU stay.

The patient subsequently improved dramatically and was rapidly weaned from ECMO, which was withdrawn after 5 days of uncomplicated treatment. He continued to make steady progress and was extubated on ICU Day 10 and discharged to the general ward 2 days later for further rehabilitation before being discharged home.

Patient 2

A 23-year-old woman, pregnant at 21 weeks' gestation, was referred to the emergency department with a 10-day history of dry cough, sore throat, fevers and myalgia. She had been treated by her general practitioner with antibiotics, but had developed postural dizziness and mucosal

CASE REPORTS

Table 1. Comparison of patients, clinical conditions, treatment, complications and outcome

Age	Sex	Pre-admission illness/condition	Severity of respiratory failure	Other rescue therapies for hypoxaemia	Associated organ failure	Complications	Outcome
33	M	Cough, fever, anorexia, haemoptysis, dyspnoea. Hypertension, diabetes and obesity	Bilateral lung infiltrates. PaO ₂ /FiO ₂ = 50	Protective lung ventilation. Nitric oxide. Prone positioning	None	None	Discharged alive
23	F	Pregnant (21 weeks). Cough, fever, sore throat, myalgia. Childhood asthma, depression	Bilateral lung infiltrates. PaO ₂ /FiO ₂ ≤ 100	Protective lung ventilation. PEEP = 15 cmH ₂ O. Nitric oxide. Prone positioning	None	Haemolysis and oozing at puncture sites. Line sepsis	Discharged alive. Infant survived
25	M	Influenza-like symptoms — cough, fever, myalgia. Heavy smoker and cannabis user. Von Willebrand's disease. Haemophilia A	Bilateral lung infiltrates. PaO ₂ /FiO ₂ ≤ 100	Protective lung ventilation. PEEP = 15 cmH ₂ O. Nitric oxide. Prone positioning. Steroids	Ischaemic cardiomyopathy, renal and hepatic dysfunction	Pneumothorax. Heparin-induced thrombocytopenia. Multiple organ failure. Gastrointestinal and bronchopulmonary bleeding. Neurological damage	Died
37	F	Pregnant (23 weeks). Cough, fever, dyspnoea. Obese. Smoker	Bibasal lung consolidation. PaO ₂ /FiO ₂ ≤ 100	Protective lung ventilation. PEEP = 20 cmH ₂ O. Prone positioning. Steroids. Inhaled aerosolised prostacyclin	None	Stillborn fetus. Critical illness polyneuropathy	Discharged alive
42	F	Pregnant (20 weeks). Influenza-like symptoms — cough, fever, myalgia	Bilateral lung infiltrates. PaO ₂ /FiO ₂ ≤ 100	Protective lung ventilation. Prone positioning. Steroids. Inhaled aerosolised prostacyclin. Sildenafil	Elective termination of pregnancy	Bleeding into the airway and from vascular access sites. Critical illness polyneuropathy	Discharged alive, underwent prolonged rehabilitation

F = female. FiO₂ = fraction of inspired oxygen. M = male. PaO₂ = arterial partial pressure of oxygen. PEEP = positive end-expiratory pressure.

purpura. She was a non-smoker with a history of childhood asthma and depression.

On admission, she had an SpO₂ of 84% on room air, with bibasal crepitations and bilateral infiltration evident on CXR. She was commenced on antibiotics, oseltamivir (75 mg twice daily) and BiPAP, but was later admitted to the ICU because of increasing BiPAP requirements and impending respiratory exhaustion.

Regular obstetric reviews and ultrasound examinations were performed during her ICU stay. H1N1 infection was confirmed on ICU Day 2 and the oseltamivir dose was increased to 150 mg twice daily.

An elective intubation was performed on ICU Day 7 due to progressive hypoxaemia and fatigue despite BiPAP. Inotropes were started because of increasing haemodynamic instability.

Venovenous ECMO was commenced on ICU Day 8 for hypoxia (SpO₂, 40%–50%) refractory to FiO₂ 1.0, positive end-expiratory pressure (PEEP) 15 cmH₂O, inverse-ratio ventilation, high-dose nitric oxide and increasing inotropic therapy. Within hours of commencement of ECMO, the FiO₂ requirement fell to 0.4 and SpO₂ stabilised to over 95%. The patient was rapidly weaned from inotropes.

During her 12-day period on ECMO, the patient received multiple red cell transfusions for persistent haemolysis and oozing at the catheter insertion sites. Recurrent fevers were managed as a possible central catheter sepsis. She had a high sedative demand, settling eventually with a thiopentone infusion.

A percutaneous (bedside) tracheostomy was sited on Day 23 and weaning of ventilatory supports proceeded. The patient was discharged from the ICU after 28 days. Her trachea was decannulated on the general ward. She was subsequently transferred to a maternity hospital for ongoing management of her pregnancy and later safely delivered a healthy baby.

Patient 3

A 25-year-old man presented to a regional hospital with a 4-day history of flu-like symptoms. A CXR showed bilateral infiltrates. The patient deteriorated rapidly and required intubation and inotropes. Antibiotics and oseltamivir (150 mg twice daily) were also commenced, and he was transferred to the ICU.

The patient had a history of von Willebrand's disease, and was a current smoker and regular cannabis user.

CASE REPORTS

On admission to the ICU, he was started on intravenous steroids and nitric oxide. He had a raised troponin level, and an echocardiogram showed global hypokinesia with an ejection fraction of 20%. Levels of liver enzymes, urea and creatinine were also raised. At this time, a history of possible prolonged hypoxaemia before and during the intubation process was obtained.

Venovenous ECMO therapy was commenced on ICU Day 3 because of continued respiratory and haemodynamic deterioration. Maximal achievable oxygen saturations prior to ECMO were 75%–80% with FiO_2 1.0 and PEEP 15 cmH_2O . H1N1 infection was confirmed 1 day later.

Despite ECMO treatment, the patient continued to deteriorate, developing a pneumothorax and declining haemoglobin levels. He was treated for nosocomial pneumonia and herpes simplex infection (identified from bronchial washings).

Haemophilia A was diagnosed, and regular factor VIII transfusions were initiated. When heparin-induced thrombocytopenia was diagnosed by standard testing, prostacyclin was substituted to achieve anticoagulation on the ECMO circuit.

Progressive multiorgan failure ensued, with acute renal failure (necessitating dialysis) and gastrointestinal stasis and bleeding. As a result of bronchopulmonary haemorrhages, the patient required multiple transfusions, repeat bronchoscopies and bronchotracheal packing. Consequently, ventilation was entirely dependent on ECMO.

Sedation was ceased on Day 27 in order to assess the patient's neurological status. He subsequently developed seizures, with unequal pupils and increasing haemodynamic instability.

Medical staff and family felt at this point that further treatment was futile, due to the likely severe hypoxic brain damage and multiple organ failure. Supportive measures were withdrawn on Day 28 and the patient died shortly thereafter.

Patient 4

A 37-year-old woman, pregnant at 23 weeks' gestation, was transferred from a regional hospital with fever, dry cough and increasing shortness of breath that had been progressing over 10 days. She had had two prior presentations to hospital during this period and had completed a course of oseltamivir that was prescribed by her GP.

H1N1 infection had been confirmed 1 day before her third presentation. At the time she was transferred to our hospital, she had been started on antibiotics and oseltamivir 150 mg twice daily. She was obese and a smoker, but had no other relevant medical history.

On the patient's arrival at SCGH, a CXR demonstrated bibasal consolidation. She had bilateral crepitations with a temperature of 38°C, a respiratory rate of 50 breaths/min

and SpO_2 89% on 15 L oxygen by facemask. She was started on continuous positive airway pressure via facemask and later intubated and transferred to the ICU.

In the ICU, nebulised prostacyclin and intravenous steroids were administered, inotropes were started and bronchoscopy was performed. She was nursed in a prone position, but oxygenation continued to worsen, reaching an SpO_2 of 60% on an FiO_2 of 1.0 and PEEP of 20 cmH_2O .

Obstetric review and ultrasound confirmed viability of the fetus.

Venovenous ECMO was started on ICU Day 2 for severe hypoxia refractory to maximal ventilatory support. Unfortunately, the patient delivered a stillborn fetus within hours of initiation of ECMO. Heparin treatment was temporarily ceased. She required a red cell transfusion but remained haemodynamically stable throughout. Her respiratory condition stabilised rapidly with ECMO, from which she was weaned over the succeeding 6 days without further complications.

A percutaneous (bedside) tracheostomy was placed on Day 12 to aid a slow ventilatory wean, in part due to profound global weakness. After an ICU stay of 18 days, the patient was discharged to the general ward for further rehabilitation, then later discharged home.

Patient 5

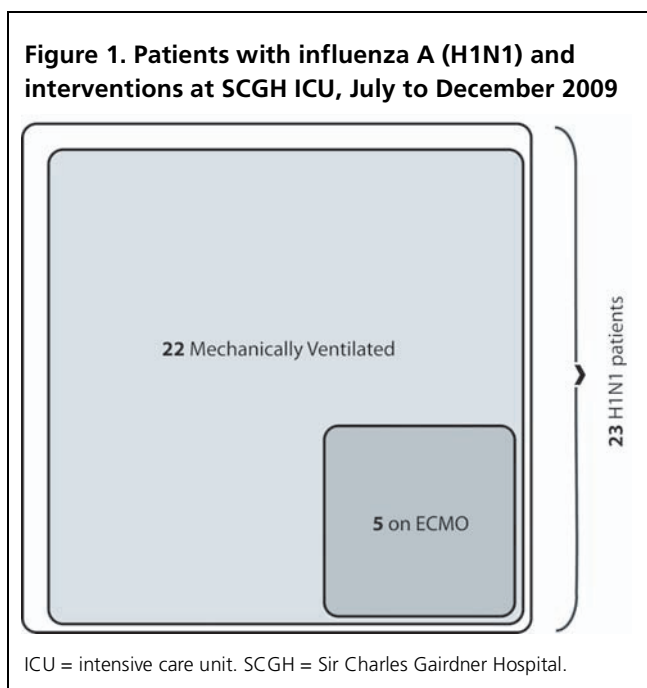
A 42-year-old woman, pregnant at 20 weeks' gestation, had presented to a regional hospital in severe respiratory distress with a 7-day history of flu-like illness. Her illness had not improved with antibiotic treatment prescribed by her GP. Shortly after admission to the regional hospital, she was intubated for severe hypoxia and transferred to SCGH. She was a non-smoker with an unremarkable medical history.

On her arrival in the SCGH ICU, a CXR demonstrated bilateral infiltrates. She was started on antibiotics, oseltamivir (150 mg twice daily), hydrocortisone and nitric oxide. H1N1 infection was confirmed. She received daily obstetric reviews and ultrasound examinations and the condition of the fetus remained stable.

The patient's respiratory condition continued to deteriorate, with worsening infiltrates visible on CXR, increasing FiO_2 requirements and recurrent fevers. An elective medical termination of pregnancy was performed on ICU Day 13.

Venovenous ECMO was commenced 3 days later because of progressive hypoxia despite prone positioning, high PEEP, inhaled prostacyclin and oral sildenafil treatment.

After initiation of ECMO, oxygen saturations stabilised, FiO_2 requirements were reduced, and the patient was weaned off inhaled prostacyclin. Red cells were regularly transfused for recurrent low haemoglobin levels, and culture-negative fevers persisted. A thiopentone infusion was needed for adequate sedation.



of its complications as for the demographic apparently most severely affected by it — young and previously well patients, with a preponderance of pregnant and obese patients.

During the 2009 influenza season in Australia and New Zealand, a total of 23 patients (with 24 admissions) were admitted to SCGH ICU for the management of severe respiratory disease caused by the H1N1 virus. Of these, 22 patients (23 admissions) required mechanical ventilation as part of their treatment strategy, of whom the five patients reported on above (representing those at the most severe end of the disease spectrum) underwent a period on ECMO as a final therapeutic option (Figure 1).

It is notable that ICU admissions for treatment of H1N1 infection have been highest in a much younger age group than is typically seen with seasonal influenza-associated critical illness. One study showed admissions to be highest among people in the 25–49 years age group,² and other studies have shown similar results.^{3–5} During the same period, the median age of patients who received ECMO was 34.4 (interquartile range, 26.6–43.1) years.⁶ Our ECMO patients had a median age of 33 (range, 23–42) years and the one non-survivor was aged only 25 years. It is thought that people over the age of 65 years may have attained a degree of immunity against the H1N1 virus, perhaps through antibody cross-reactivity after years of annual seasonal influenza vaccination.⁷

Of our five ECMO patients, only one had a chronic underlying medical condition. This correlates with international observations that, compared with patients with seasonal influenza virus, an unusually high proportion of patients with H1N1 influenza were free of major comorbidities before becoming unwell.^{2,3,5,8} Two of our patients were clinically obese and three (of three females) were pregnant. Again, this is in line with international data showing a higher proportion of obese^{2,4,5} or pregnant² patients among critically ill patients with H1N1 influenza than in the general population.

Our patients had ECMO cannulae inserted peripherally into the femoral or jugular or both vessels. The procedure was carried out either in the ICU or in the cardiothoracic theatre. All patients had two drainage cannulae and one return cannula (all 21 French gauge) inserted, enabling high-flow therapy. The circuit layout is shown schematically in Figure 2. Fresh gas and blood flows (powered by the centrifugal pump) were aimed at a V/Q match of 1:1 (eg, 5 L/min oxygen into the oxygenator and 5 L/min blood), and the patients were continued on a standard protective ventilation mode for the duration of their time on ECMO. Heparin was infused through the circuit and titrated, under normal circumstances, against a desired activated partial thromboplastin time of 50–55 seconds.

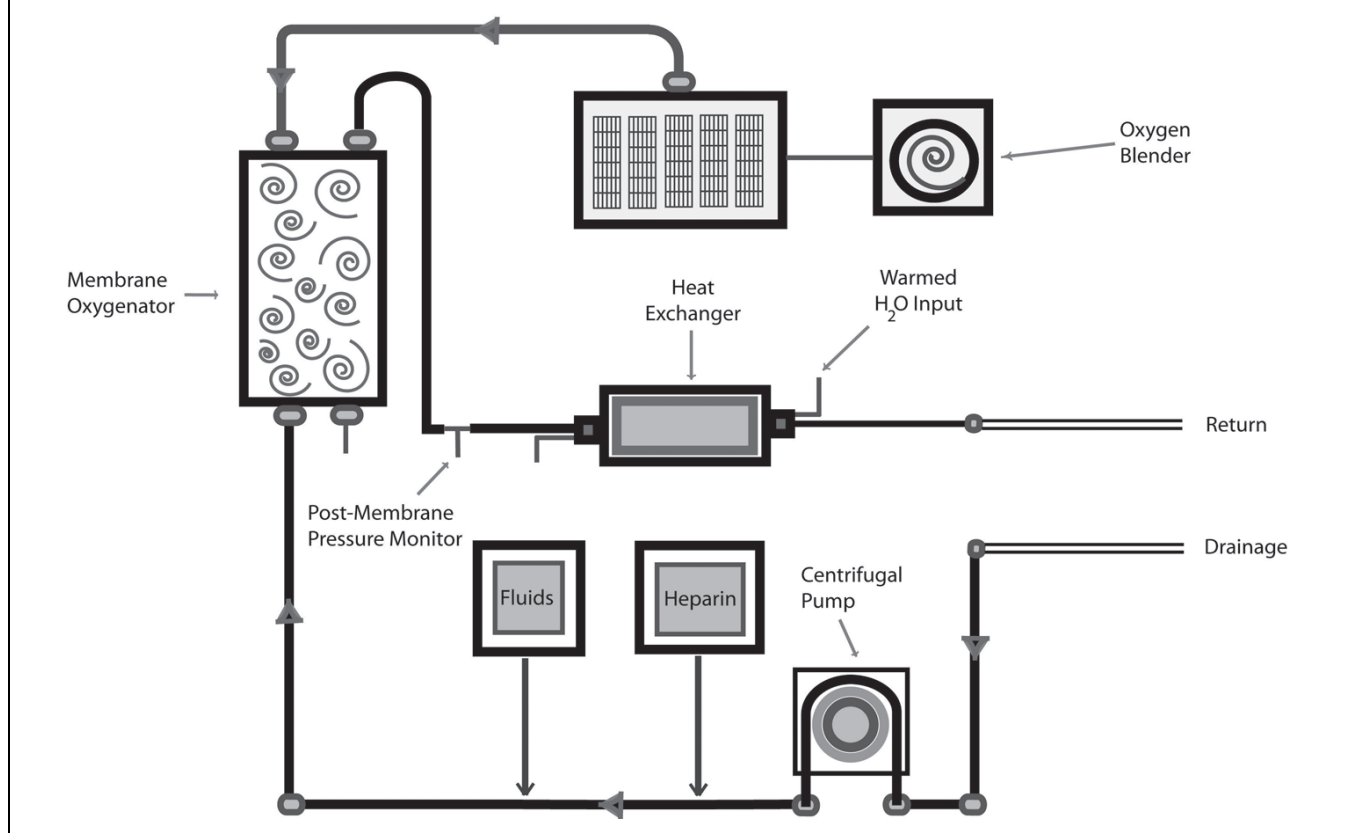
A percutaneous (bedside) tracheostomy was sited on Day 20. Two days later, two large blood clots caused a complete obstruction of the right main bronchus, with a sudden inability to ventilate. Fresh blood was brought up via the tracheostomy. Platelets and red cells were transfused and heparin targets were revised downward. The patient stabilised, but central catheter insertion sites continued to ooze intermittently.

After 21 days and daily trials on reduced support, the decision was made to fully withdraw ECMO therapy, as the risks of bleeding and infection were felt to be potentially more detrimental than the benefits the patient was deriving from ongoing treatment.

An extremely slow weaning process was further compounded by a profound critical illness polyneuropathy, a number of culture-positive infections and severe anxiety. Ventilatory support was fully ceased on ICU Day 78, and the woman was discharged to the general ward 6 days later. She was subsequently transferred to a specialist unit for further rehabilitation.

Discussion

Infection by the influenza A (H1N1) 2009 virus can lead to rapidly progressive respiratory failure and the development of acute respiratory distress syndrome (ARDS). ECMO is generally accepted as a means of respiratory support in cases of severe hypoxaemia, hypercapnia, or both, when they are refractory to maximal conventional therapies and where there is a potentially reversible cause. However, the 2009 H1N1 strain is as remarkable for the potential severity

Figure 2. Schematic representation of the extracorporeal membrane oxygenation circuit

Bleeding and infection were the most common complications experienced by our ECMO patients. Bleeding was seen in four of the five patients and was a major contributing factor to the death of the one non-surviving patient. Three of the five patients developed sepsis while undergoing treatment. Difficulties achieving adequate levels of sedation were noted in two patients, possibly due to factors such as increased volume of distribution and increased total cardiac output, with increased clearance.

Weaning off ECMO was started when tidal volumes increased (to the range of 4–6 mL/kg) and lung appearance on CXR improved, implying an increase in lung compliance. This was done by turning the oxygen to the oxygenator off, turning the patient's FiO_2 to 1.0 and monitoring his or her tolerance of this over a trial time period.

The median ECMO duration was 12 (range, 5–26) days and the total duration of ECMO support provided in the ICU was 70 days. From data available for four of our five patients, we estimated the cost of ECMO per patient per day to be \$1965, based on the cost of disposables, medications, fluids and staffing. Additional specialist staff required to provide the service included ECMO-trained nurses, perfusionists and cardiothoracic surgeons.

During the 2008 winter period (1 June to 31 August), only four patients received ECMO for ARDS in Australia and New Zealand.⁶ During the same period in 2009, 15 of approximately 200 ICUs provided ECMO for 68 H1N1 patients alone.⁶ Overall, the SCGH ICU experience of ECMO during the 2009 H1N1 influenza pandemic was an extremely positive one. Four of five patients who remained critically hypoxaemic after maximal conventional therapies had a successful outcome after a period on ECMO. However, the high demand on hospital resources, the need for specialist training and the potentially catastrophic complications associated with ECMO (eg, massive bleeding, circuit disconnection) mean that it remains a treatment of last resort and is currently appropriate for only a small subset of critically ill patients. However, as our skill base increases and our ability to better prevent and manage complications improves, it is likely that future influenza seasons will see increasing numbers of severely ill patients offered ECMO, given the potential advantages it offers in reducing deaths associated with H1N1-induced ARDS.

Acknowledgement

We would like to thank Oleg Erkhov for design of the graphics.

CASE REPORTS

Author details

Clodagh A M Power, Resident

P Vernon van Heerden, Intensive Care Physician

David Moxon, Intensive Care Physician

Graham Martindale, Nurse Manager

Brigit Roberts, Research Coordinator

Department of Intensive Care, Sir Charles Gairdner Hospital, Perth, WA, Australia.

Correspondence: powercl@tcd.ie

References

- 1 World Health Organization. Pandemic (H1N1) 2009 — update 92. http://www.who.int/csr/don/2010_03_19/en/index.html (accessed Mar 2010).
- 2 ANZIC Influenza Investigators; Webb SA, Pettilä V, Seppelt I, et al. Critical care services and 2009 H1N1 influenza in Australia and New Zealand. *N Engl J Med* 2009; 361: 1925-34.
- 3 Kumar A, Zarychanski R, Pinto R, et al; Canadian Critical Care Trials Group H1N1 Collaborative. Critically ill patients with 2009 influenza A (H1N1) infection in Canada. *JAMA* 2009; 302: 1872-9.
- 4 Dominguez-Cherit G, Lapinsky SE, Macias AE, et al. Critically ill patients with 2009 influenza A (H1N1) in Mexico. *JAMA* 2009; 302: 1880-7.
- 5 Intensive care patients with severe novel influenza A (H1N1) virus infection — Michigan, June 2009. <http://www.cdc.gov/mmwr/PDF/wk/mm58d0710.pdf> (accessed Dec 2009).
- 6 Australia and New Zealand Extracorporeal Membrane Oxygenation (ANZ ECMO) Influenza Investigators; Davies A, Jones D, Bailey M, et al. Extracorporeal membrane oxygenation for 2009 influenza A (H1N1) acute respiratory distress syndrome. *JAMA* 2009; 302: 1888-95.
- 7 Centers for Disease Control and Prevention (CDC). Serum cross-reactive antibody response to a novel influenza A (H1N1) virus after vaccination with seasonal influenza vaccine. *MMWR Morb Mortal Wkly Rep* 2009; 58: 521-4.
- 8 Perez-Padilla R, de la Rosa-Zamboni D, Ponce de Leon S, et al. Pneumonia and respiratory failure from swine-origin influenza A (H1N1) in Mexico. *N Engl J Med* 2009; 361: 680-9. □