

Activated Protein C in Toxic Shock Syndrome: A Case Report

K. S. RACHAKONDA

Department of Critical Care, Wollongong Hospital, Wollongong, NEW SOUTH WALES

ABSTRACT

The mortality from septic shock remains high despite the availability of modern critical care facilities. In recent years, new agents have been tested to reduce morbidity and mortality in patients with severe sepsis. Among them, recombinant human activated protein C (rhAPC) has been reported to significantly reduce mortality and morbidity in patients with severe sepsis and one or more acute organ failures. We describe our experience with this drug in the early reversal of septic shock from toxic shock syndrome. (Critical Care and Resuscitation 2003; 5: 189-192)

Key words: Septic shock, toxic shock syndrome, activated protein C, thrombosis, inflammation, cytokines

Toxic shock syndrome (TSS) presents with a high fever, profuse watery diarrhoea, headache, confusion and severe erythroderma with oliguric renal failure and was first reported by Todd *et al.*¹ It is most frequently seen in menstruating women but may occur in either sex and at any age. Tampon use, septic abortions, surgical wound sepsis, cutaneous and subcutaneous infections and penetrating wounds have all been incriminated in the pathogenesis of this syndrome.² Over 90% of menstrual TSS and 60% non-menstrual TSS is associated with a *Staphylococcus aureus* toxic shock syndrome toxin-1, which is a potent inducer of interleukin-1 production.³

A case of TSS with resistant hypotension and poor peripheral perfusion which reversed in association with an infusion of recombinant human activated protein C (rhAPC) is presented.

CASE REPORT

A 53-year-old Caucasian male presented to the emergency department with a two-day history of severe watery diarrhoea, cough, upper abdominal pain and widespread skin rash. Four weeks prior to his presentation, he was treated with antibiotics for a work-related penetrating left knee injury. Although the initial response was satisfactory, there was a progressive increase in swelling to his left knee and an increase in malaise a few days prior to his current admission. He had a past

history of deep venous thrombosis in the left calf muscle and his normal daily medication was 150 mg of aspirin.

On examination, he had poor peripheral perfusion and a widespread rash over his body. He was in sinus rhythm at a rate of 140 beats per minute, his respiratory rate was 40 per minute and his core temperature was 40°C. The skin perfusion to both feet below his ankles was severely compromised (Figure 1) and no pulse could be clinically detected to either of his lower limbs below the knee. He also had abdominal guarding over the right upper quadrant, widespread basal crackles on chest auscultation and he remained oliguric.

The admission, the complete blood picture and coagulation profile was consistent with sepsis, dehydration and disseminated intravascular coagulation (Table 1). The plasma biochemical profile revealed a creatinine of 0.674 mmol/L, urea 15 mmol/L and anion gap 26 mEq/L. The plasma ALT was 145 U/L and CK 2692 U/L indicating early rhabdomyolysis with multi organ failure (Table 2). His admission APACHE-II score was 29. An abdominal ultrasound revealed no obvious visceral abnormalities.

A clinical diagnosis of toxic shock syndrome (TSS) was made and the patient was admitted to the intensive care unit for further management. He was intubated, mechanically ventilated and fluid and inotropic therapy were administered (Table 2) depending on lung water

Correspondence to: Dr. K. S. Rachakonda, Intensive Care Unit, Wollongong Hospital, Wollongong, New South Wales 2500 (e-mail: rachakondas@iahs.nsw.gov.au)

and continuous cardiac output measurements derived from a pulse index continuous cardiac output computer (Pulsion Pacific®). Early continuous haemodiafiltration was initiated to correct the acid base and electrolyte derangements. Empirical antibiotic therapy, with specific cover against staphylococcus aureus, was prescribed using meropenem 500 mg 8-hourly and dicloxacillin 1 g 6-hourly for 72 hrs then vancomycin 1 g daily.

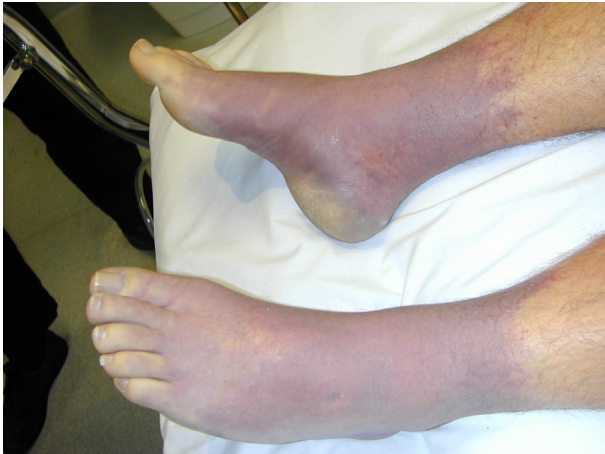

Figure 1. Severe circulatory compromise to both feet on admission to the intensive care unit.

During the first 24 hours he required increasing doses of vasoactive agents. The circulation to both feet below the ankles showed no clinical improvement and clinically there appeared to be an impending threat to the circulation of his upper limbs (Figure 2).

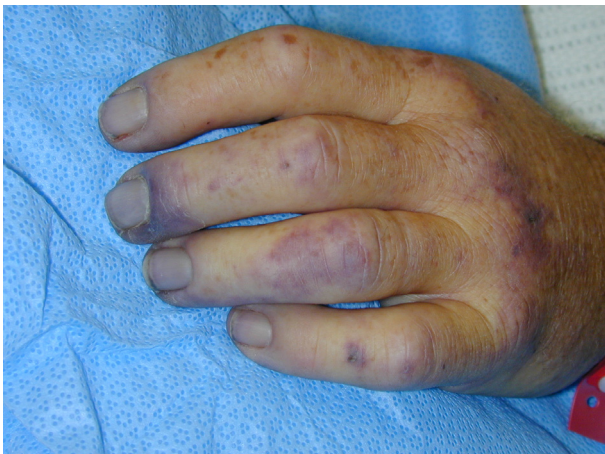

Figure 2. Circulatory compromise developing in the hands of the patient during the first 24 hours of treatment in the intensive care unit.

In an attempt to reverse the thrombotic and inflammatory process we decided to use a 96 hour infusion of rhAPC [drotrecogin alfa (activated)]

Xigris®. Before therapy was initiated, the plasma protein C level was 13 Units (normal range 80-151 units). The patient received platelets twice during the 48 hours following initiation of the rhAPC infusion. During the next 5 days the patient slowly recovered, allowing all vasopressor agents to be discontinued and the circulation to the upper extremities significantly improved. Towards the end of first week he showed the typical desquamation of TSS of his whole body including the oropharyngeal mucous membranes (Figure 3 and Figure 4). All blood, sputum, and urine cultures remained negative.

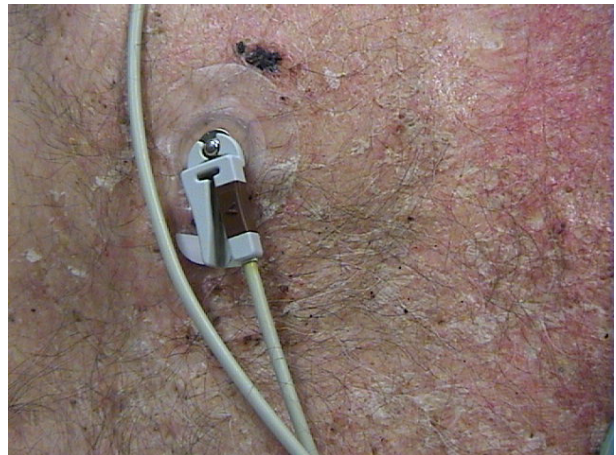


Figure 3. Desquamation of skin 7 days after admission to the intensive care unit.

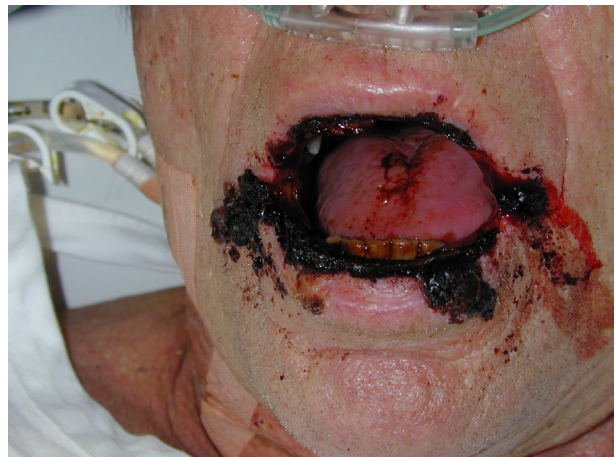

Figure 4. Oropharyngeal mucous membrane desquamation 7 days after admission to the intensive care unit.

Although the patient recovered from the haemodynamic disorder, he developed acute tubular necrosis and required further haemodialysis. He was weaned from mechanical ventilation and was extubated by the ninth day. Aortography was performed on the 10th day

Table 1. Haematological and biochemical parameters (normal range) before and after the rhAPC infusion

Day	WBC (x 10 ⁹ /L) (3.5 - 11)	Hb (g/L) (130 - 180)	Plt (x 10 ⁹ /L) (150 - 450)	APTT (25 - 42)	INR (0.8 - 1.1)	D-dimer (mg/L) (0.00 - 0.5)	rhAPC (24 µg/kg/hr)
0	11.2	165	212	48.1	2	> 1.6	
1	16.8	116	108	247.2	2.9	1.6	Started
2	22.4	118	33	117.7	1.7	1.6	
3	37.6	106	37	91.1	1.7	1.6	
4	41.3	96	40	45.4	1.4	0.8	
5	27.8	92	35	34.8	1.3	0.8	Finished

WBC = White blood cell count, Hb = Haemoglobin, HCT = Hematocrit, Plt = Platelets, APTT = Activated partial thromboplastin time, INR = International normalisation ratio, rhAPC = recombinant activated protein C.

Table 2. Summary of therapy until the completion of recombinant human activated protein C infusion

Day	24 hr fluid balance (mL)	Noradrenaline (mg/ 24 hr)	Adrenaline (mg/24 hr)	Vasopressin (µg/24 hr)	Hydrocortisone (mg/24 hr)	rhAPC 24 µg/kg/hr
0	+4522	19.5	3.84	0	250	
1	+5622	32.5	8.58	0	200	Started
2	+2162	21.2	8.64	44	200	
3	+1161	12.1	8.58	102	0	
4	-375	3.36	3.5	0	0	
5	-2338	0	0	0	0	Finished

rhAPC = recombinant human activated protein C

and demonstrated no circulation to the lower limbs below popliteal vessels, so a bilateral below knee amputation was performed. He spent two weeks in the intensive care unit before he was discharged to the ward. Subsequently he left the hospital with artificial limbs fitted to both his feet. A follow-up at ten months after his illness, revealed that the patient had a reasonable quality of life and he was actively pursuing a return to work.

DISCUSSION

Our patient fulfilled most of the criteria for TSS case definition proposed by the US Centres for Disease Control and Prevention.² Severe mucosal desquamation and ulceration of the oropharyngeal and genital mucosa, usually occurs during the resolution phase of the disorder, and was observed in our patient (Figure 5 and Figure 6).

Use of rhAPC as an adjuvant therapy in shock due to TSS has not been reported previously. We used the agent in an attempt to reverse the adverse inflammatory and thrombotic process underlying septic shock. In our report the vasoactive agents were rapidly weaned following its use and the circulation to the upper extremities also improved. In a recent multicentre trial in patients with severe sepsis and one or more acute organ failures,⁴ plasma levels of interleukin-6 were significantly lower in patients treated with rhAPC

compared with placebo. Since the toxic shock syndrome toxin-1 is a potent inducer of interleukin-1, rhAPC may have had a similar inhibitory effect on interleukin-1 levels⁴ in our patient with TSS.

The view that functional adrenal insufficiency is common in severe sepsis⁵ has promoted the use of low dose hydrocortisone supplementation to correct any functional hypoadrenalism as well as reduce catecholamine requirements in septic shock.^{6,7} However, hydrocortisone had little effect in our patient, necessitating the consideration of other agents. While it is difficult to speculate the contribution of vasopressin in the early cessation of inotropic agents in our patient, its predominant effect is vasoconstriction and the clinical feature of a progressive compromised circulation of both upper and lower limbs in our patient prompted us to consider rhAPC. While receiving rhAPC, additional anticoagulant was not needed to facilitate CVVHDF supporting the clinical antithrombotic properties of rhAPC previously observed *in vitro*.⁸⁻¹⁰

Received: 19 May 2003

Accepted: 6 July 2003

REFERENCES

1. Todd J, Fishaut M, Kapral F, Welch T.O. Toxic shock syndrome associated with phage-group 1 staphylococci. *Lancet* 1978;2:1116.

2. Sivak E D, Higgins T L, Seiver A. The high-risk patient: Management of critically ill. William and Wilkins 1995:931-936.
3. Parsonnet J, Hickman R K, Eardley D D, Pier G B. Induction of human interleukin-1 by Toxic shock syndrome toxin-1. *J Infect Dis* 1985; 151: 514.
4. Bernard G R, Vincent J L, et al. Efficacy and Safety of recombinant human activated protein C for severe sepsis. *N Eng J Med* 2001; 344:699-709.
5. Cooper M S, Stewart P M. Corticosteroid insufficiency in acutely ill patients. *N Engl J Med* 2003;348:727-34.
6. Briegel J, Frost H, Haller M et al. Stress dose of hydrocortisone reverse hyperdynamic septic shock: A prospective randomised, double-blind, single center study. *Crit Care Med* 1999;27:723-32.
7. Annane D, Sebille V, Carpentier C, et al. Effect of treatment with low dose hydrocortisone and fludrocortisone on mortality in patients with septic shock. *JAMA* 2002; 288:862-71.
8. Grey S T, Tsuchida A, Hau H, Orthner C L, Salem H H, Hancock WW. Selective inhibitory effect of anticoagulant activated protein C on the response of human mononuclear phagocytes to LPS, IFN-gamma or Phorbol ester. *J Immunol* 1994;153 :3664-72.
9. Walker F J, Sexton P W, Esmon C T. The inhibition of blood coagulation by activated protein C through selective inactivation of activated factor V. *Biochem Biophys Acta* 1979; 571: 333-42.
10. Fulcher CA, Gardiner JE, Griffin JH, Zimmerman TS. Proteolytic inactivation of human factor VIII procoagulant protein by activated human protein C and its analogy with Factor V. *Blood* 1984; 63; 486-9.