

# Percutaneous coronary intervention in the 21st century — making surgeons irrelevant?

Mark R Adams

The past decade has seen massive changes in the practice of medicine and surgery, none greater than in the field of interventional cardiology, where the technological developments at times outstrip the evidence base for their best utilisation. During the early 1990s, the development of coronary stenting made percutaneous coronary intervention (PCI) safer and more effective, but a number of challenges remained. These included the need for surgical backup during PCI, correct choice of treatment for multivessel disease, in-stent restenosis, stent thrombosis, chronic total occlusions, prevention of embolisation in vein graft lesions, and treatment of non-coronary disease, such as atrial septal defects and valve replacements. Many of these problems have been largely resolved, as discussed below. As a result, the utilisation of PCI has greatly increased, with stenting being the preferred option in many cases, such as single-vessel disease and acute myocardial infarction (Figure 1A). Currently, many situations now have percutaneous as well as surgical options, and close cooperation is needed between the interventional cardiologist and the surgeon to achieve the best solution for the individual patient.

## Changing interaction between PCI and CABG

Early experience with balloon angioplasty was characterised by the need for “rescue” coronary artery bypass grafting (CABG) in as many as 20% of patients. However, with the widespread use of coronary stents and the availability of effective antiplatelet agents, this rate has recently fallen to less than 0.5% (Figure 1B). This has led some investigators to question the need for surgical support at every centre performing PCI, particularly in cases of acute myocardial infarction. However, the ready availability of cardiac surgical support may be life-saving in the event of coronary artery perforation with tamponade, or left main coronary artery occlusion.<sup>1</sup>

There have been many technical improvements in cardiac surgery in recent years, but immediate postoperative ischaemia remains a significant problem. In fact, postoperative myocardial infarction has been reported to occur in 5%–10% of cases, and may account for 60%–70% of in-hospital mortality. Balloon angioplasty of coronary artery bypass grafts was first described over 10 years ago, and several series have described immediate success rates of 90%–94%.<sup>1</sup> The availability of coronary stents has further

## ABSTRACT

Interventional cardiology is a rapidly changing area, with technical improvements allowing us to treat an increasing number of clinical situations by percutaneous methods. Indeed, the interface between interventional cardiologist and cardiac surgeon has changed in the past decade, with a dramatic reduction in the need for “rescue” surgery. The most significant recent development has been drug-eluting stents, which have dramatically reduced the rates of restenosis, although at the cost of a need for longer-term antiplatelet therapy after implantation. Failure to continue this antiplatelet therapy may lead to a small but significant excess of stent thrombosis. There have been many other technological improvements, such as distal protection devices and better guidewires for crossing occluded vessels, as well as percutaneous devices for treating valve disease and other structural cardiac abnormalities. These technologies are often best developed in a combined approach with cardiac surgeons, and the selection of the best treatment more than ever requires close cooperation between cardiologist and surgeon.

Crit Care Resusc 2007; 9: 370–373

added to the potential for rescue interventional procedures following failed CABG, although the high success rate of simple balloon angioplasty has meant that stents have only commonly been employed when balloon angioplasty has yielded a suboptimal result.

Both PCI and CABG have proven effective in controlling the symptoms of myocardial ischaemia. In many cases, both interventional and cardiac surgical procedures may be reasonable treatment alternatives. The choice of treatment should be individualised and requires careful consideration of evidence from the published medical literature, and patient preferences. The patient may benefit from close collaboration between the interventional cardiologist and the cardiac surgeon. Although the need for “rescue” cardiac surgery following PCI has greatly diminished, in certain cases it is life-saving. In addition, PCI can effectively treat failed grafts and residual ischaemia following CABG. Close cooperation between the cardiac surgeon and the interventional cardiologist may also offer the opportunity to

## POINTS OF VIEW

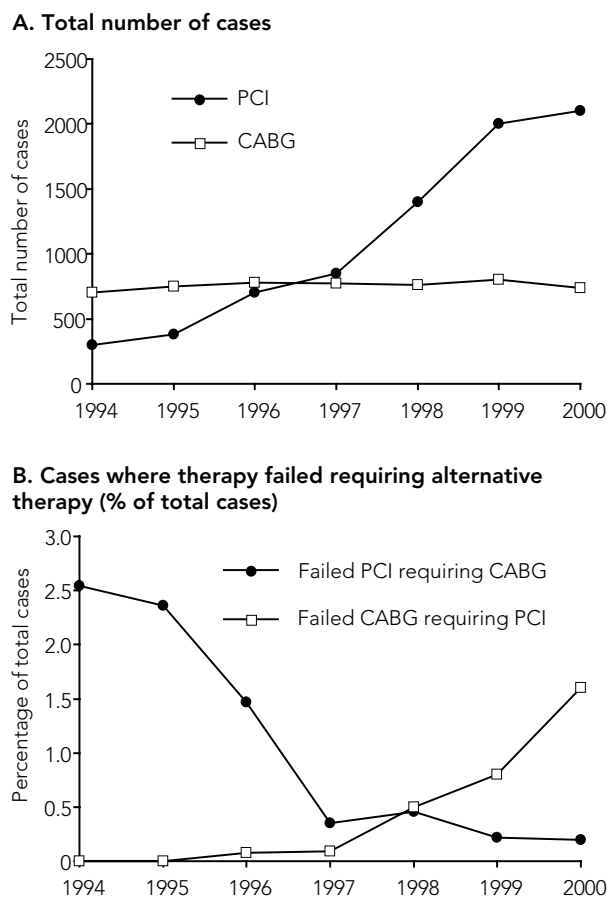
develop new strategies to treat myocardial ischaemia. For example, a combination of PCI techniques and minimally invasive cardiac surgery may facilitate protected treatment of left main coronary artery stenosis, or complete revascularisation without the need for cardiopulmonary bypass. It is possible that these changing patterns of resource utilisation will need to be considered when planning hospital facilities and organising patient triage.

### Benefits of revascularisation

Independent of the method of revascularisation — surgery or PCI — survival benefit is seen only with certain coronary anatomies (three-vessel or left main coronary disease) or in certain clinical situations, such as unstable angina and acute myocardial infarction.<sup>2</sup> A recent randomised trial conducted by the Department of Veterans Affairs in the United States confirmed that, as a treatment for stable angina symptoms, PCI is effective at improving quality of life and reducing angina but, compared with modern medical therapy, has no mortality benefit.<sup>3</sup>

PCI has very much become the treatment of choice in acute coronary syndromes, with most major hospitals offering 24-hour access to primary PCI for ST-elevation myocardial infarction,<sup>4</sup> but there has been much debate over the best approach to treatment of three-vessel disease and left main coronary disease. Both approaches have potential benefits and pitfalls and, although a large number of randomised trials have been conducted on this group, the data are often difficult to apply to current practice because of the rapid pace of technological advancement. For example, one of the most often cited trials, BARI (Bypass Angioplasty Revascularization Investigation), was performed before the routine use of stents and before the advent of modern antiplatelet agents.<sup>5</sup> Nevertheless, meta-analysis of the major trials has failed to show a difference between CABG and PCI<sup>5</sup> in terms of survival or myocardial infarction. Although PCI was associated with a higher rate of need for repeat procedures in many of the trials, there are few data from trials using modern drug-eluting stents. In the one trial that addressed this issue, ARTS II (Arterial Revascularization Therapy Study), the results are encouraging for an approach using drug-eluting stents. At 1 year post-procedure, the 89.2% of patients treated by PCI were free of major adverse cardiac events, compared with 88.4% of historical CABG controls and 73.5% of historical PCI controls. A number of trials addressing this area are underway, such as FREEDOM (Future Revascularization Evaluation in Patients with Diabetes Mellitus: Optimal Management of Multivessel Disease) and COMBAT (Comparison of Bypass Surgery and Angioplasty using Sirolimus-Eluting Stents in Patients with Left Main Coronary Disease). However, in the meantime, it appears that, in

**Figure 1. Use of percutaneous coronary intervention and coronary artery bypass grafting to treat myocardial ischaemia at Brigham and Women's Hospital, Boston, United States<sup>1</sup>**



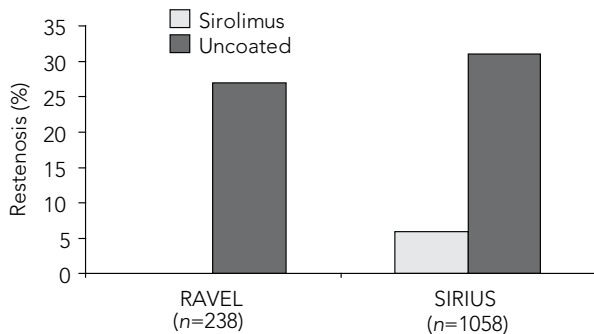
**A.** The use of percutaneous coronary intervention (PCI) for the treatment of myocardial ischaemia greatly increased over the 1990s, although coronary artery bypass graft (CABG) surgery continued to be the treatment of choice in many cases.  
**B.** The need for "rescue" CABG surgery for failed PCI decreased between January 1994 and March 2000. There was a simultaneous increase in the use of "rescue" PCI for failed CABG, such that by 2000 these events occurred with similar frequency.

patients who require revascularisation for symptom control or prognostic benefit, PCI is often the most convenient solution, and with advancing technology more patients are potentially treated this way. Ultimately, the selection of revascularisation technique may depend on a variety of clinical factors or, indeed, patient preference.

### Limitations of percutaneous coronary intervention

Even with the use of coronary stents, restenosis after PCI has been the greatest limitation to its clinical application;

**Figure 2. Rates of restenosis in drug-eluting (sirolimus) and bare-metal stents in the RAVEL<sup>6</sup> and SIRIUS<sup>7</sup> trials**



Initial clinical trials of drug-eluting stents showed a dramatic reduction in rates of angiographically detected in-stent restenosis, with rates as low as 0% in the RAVEL trial.

for example, in diabetic patients with coronary vessels less than 2.5 mm in diameter, restenosis rates approach 40%.<sup>5</sup> In the past decade, there have been great advances in our understanding of the pathophysiology of this process, which have led to better prevention strategies and treatments for restenosis. Some of these approaches are quite innovative, such as coating the stent surface with antibodies to bind circulating endothelial progenitor cells and promote rapid re-endothelialisation of the injured vessel. However, the most studied approach at present is the use of drug-eluting stents. A variety of these devices are now commercially available, but all comprise a metallic stent coated with a polymer, in which is embedded a drug such as paclitaxel or sirolimus, which elutes over time. These drugs act by inhibiting the proliferation of smooth muscle cells in the vessel wall, which are responsible for the restenosis process within the stent. The results of trials comparing these stents with earlier bare-metal stents have been unprecedented, with zero restenosis rates in some (Figure 2). Even in high-risk subsets, such as patients with diabetes, or in the treatment of vein graft lesions, the results have revolutionised the approach to stenting, not only giving better and more durable angiographic results, but allowing the treatment of more complex lesions.<sup>4</sup>

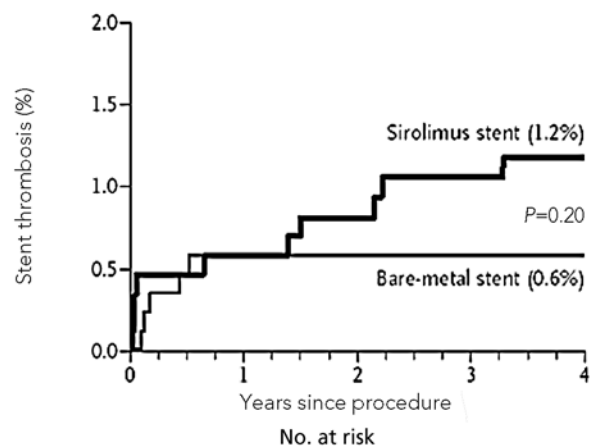
Although these stents have represented a great technological advance, there remain a number of problems. The major limitation has been the effect that the drug has on normal healing of the vessel wall after the stent-induced injury, with delayed re-endothelialisation and hence propensity to thrombosis if all antiplatelet agents are discontinued in the first year after the procedure<sup>4</sup> (Figure 3). Fortunately, late stent thrombosis is extremely rare when dual antiplatelet therapy with aspirin and clopidogrel is

continued, and most cases that occur after the first 6 months follow discontinuation of both agents. As a result, careful consideration is required before stent selection, particularly if a potential need to stop antiplatelet therapy is identified, such as an impending surgical procedure, a bleeding problem or iron-deficiency anaemia. Of course, as many patients are elderly and have comorbidities, unplanned surgery is often needed. In these cases, it is important to remember that cessation of both aspirin and clopidogrel may carry a significant risk of perioperative myocardial infarction.

Embolisation of atheroma and thrombus has been identified as a particular problem in some lesions, particularly in the treatment of saphenous vein graft disease and acute lesions in native coronary arteries with associated thrombus. In recent years, a number of distal protection devices have been developed. These devices are often deployed distally to vein graft lesions before balloon dilatation and stent deployment. A number of trials have shown that this reduces the incidence of procedure-related adverse events. For example, the SAFER (Saphenous Vein Graft Angioplasty Free of Emboli Randomized) trial showed a reduction in myocardial infarction from 14% to less than 8%.<sup>5</sup> Unfortunately, the results of these devices have been disappointing in native vessels, and they may be useful only in particular lesion subsets.<sup>5</sup>

The treatment of chronic total occlusions (ie, occlusions of more than 6 months' duration) is a remaining limitation of PCI, with success rates in the order of 70% for most

**Figure 3. Stent thrombosis by time for drug-eluting (sirolimus) and bare-metal stents<sup>8</sup>**



	870	852	833	806	742
Bare-metal	870	852	833	806	742
Sirolimus	878	854	826	795	732

A number of trials and registries have noted a small excess of stent thrombosis occurring later than 6 months with drug-eluting stents. This was extremely uncommon with plain bare-metal stents.

## POINTS OF VIEW

operators, with outcome determined by a number of operator and lesion-related factors. As these lesions represent around 5%–10% of the case-load, this is a significant problem. The recent significant improvement in guidewire design and technology has increased the success rate, although these procedures remain technically demanding. A number of innovations are under development, but clinical use is limited. For example, devices have been developed that aid identification of the true arterial lumen distal to the lesion, including the use of low coherence light and radiofrequency energy from the guidewire tip to confirm that forward force is directed to the vessel lumen.<sup>5</sup>

### New applications of percutaneous techniques

Recently, many proceduralists have begun treating carotid artery and other peripheral vascular disease, as well as coronary artery disease. This has led to the development of what is almost a new specialty — the cardiovascular interventionist. In addition, a number of devices have become available for treating conditions previously only treatable by cardiac surgery. These include alcohol septal ablation, percutaneous closure of atrial septal defects, percutaneous valve replacement and sealing of left atrial appendages.

In alcohol septal ablation, alcohol is injected into septal arteries to treat hypertrophic obstructive cardiomyopathy. This technique has been adopted in many centres that specialise in this condition. In most cases, it offers a more predictable result than surgical myectomy, which is technically demanding, particularly when surgeons do not perform large numbers of these operations.<sup>9</sup> Percutaneous closure of atrial septal defects, patent foramen ovale, patent ductus arteriosus and some ventricular septal defects has become a routine procedure over the past 8 to 10 years, with a number of devices available for implantation. An enormous number of other devices are under development for the treatment of cardiovascular disease. An active area of development is percutaneous valve replacement, particularly for aortic valve disease, where patients are often quite elderly. Although these devices are in their infancy and constantly being refined, the proce-

cedure has been performed successfully in a significant number of patients.

### Conclusions

Interventional cardiology is a rapidly changing area, with technical improvements allowing an increasing number of clinical conditions to be treated by percutaneous methods. These include both coronary and non-coronary conditions, where surgery was previously the only option. These technologies are often best developed in a combined approach that includes cardiac surgeons, and the selection of the best treatment more than ever requires close cooperation between cardiologist and surgeon.

### Author details

Mark R Adams, Head of Department

Department of Cardiology, Royal Prince Alfred Hospital, Sydney, NSW.

**Correspondence:** markadams@email.cs.nsw.gov.au

### References

- 1 Adams MR, Orford JL, Blake GJ, et al. Cardiac catheterization laboratory backup for cardiac surgery: a changing pattern. *Clin Cardiol* 2001; 25: 280-6.
- 2 Yusef S, Zucker D, Peduzzi P, et al. Coronary artery bypass grafting versus medical therapy for multivessel disease: a meta analysis. *Lancet* 1994; 344: 563-70.
- 3 Boden WE, O'Rourke RA, Teo KK, et al. Optimal medical therapy with or without PCI for stable coronary disease. *N Engl J Med* 2007; 365: 1503-16.
- 4 Dixon SR, Grines CL, O'Neill WW, et al. The year in interventional cardiology. *J Am Coll Cardiol* 2006; 47: 1689-706.
- 5 Holmes DR, Berger PB. Complex intervention. In: Topol E, editor. *Textbook of interventional cardiology*. 4th ed. Philadelphia: Saunders, 2003: 201-22.
- 6 Cufman GD. Sirolimus-eluting coronary stents. *N Engl J Med* 2002; 346: 1770-4.
- 7 Windecker S, Remondino A, Eberli FR, et al. Sirolimus and paclitaxel-eluting stents for coronary revascularization. *N Engl J Med* 2005; 353: 653-60.
- 8 Stone GW, Moses JW, Ellis SG, et al. Safety and efficacy of sirolimus and paclitaxel-eluting coronary stents. *N Engl J Med* 2007; 356: 998-1002.
- 9 Sigwart U. Non-surgical myocardial reduction for hypertrophic obstructive cardiomyopathy. *Lancet* 1995; 346: 211-4. □