

Cooling in the tropics: ethylene glycol overdose

Adam L Holyoak, Todd A Fraser and Pascal Gelperowicz

Ethylene glycol is commonly found in radiator coolant/antifreeze in varying concentrations. It is readily available within the community and, particularly in Europe and America, has been used in suicide attempts.¹⁻⁵ Accidental swallowing of ethylene glycol by children has also occurred, with the bright colouring of the coolant mixture likely proving attractive.^{2,4,5}

Ethylene glycol has a sweet taste and is rapidly absorbed via the gastrointestinal mucosa.^{2,5-7} Initial symptoms of intoxication are similar to those caused by other alcohols, but if untreated, the intoxication can lead to coma, renal failure and severe metabolic acidosis, which, without intervention, almost invariably ends in death.^{1,2,6,8-11}

Treatment for ethylene glycol poisoning involves the blockade of metabolic enzymes (specifically alcohol dehydrogenase [ADH]) with fomepizole or saturation of the enzymes with preferentially metabolised compounds (eg, ethanol).^{1,2,4,11-13} These treatments are usually administered parenterally, although ethanol may also be given enterally.^{2,11}

We report a case of severe ethylene glycol poisoning that was treated with enteral ethanol with good effect.

Clinical record

A 23-year-old male tourist was found unconscious in his motel room by cleaning staff and brought to the emergency department by ambulance. His room contained broken light bulbs (which had been used to cut his wrists), exposed electrical wires, and a 4 L bottle of antifreeze (60% ethylene glycol) which had about 1.5 L remaining inside it. The patient's vital signs on arrival at the emergency department are shown in Table 1. Initial examination revealed a Glasgow Coma Score of 3, Kussmaul respirations, equal but non-reactive 3 mm pupils, evidence of urinary incontinence, superficial lacerations to both wrists, and no obvious evidence of electrocution (such as entry or exit burns). Physical examination was otherwise unremarkable. An electrocardiogram showed normal sinus rhythm. The patient was intubated and ventilated on arrival. Results of arterial blood gas analysis, full blood count, coagulation profile and serum biochemistry are summarised in Table 2. Arterial blood gas analysis revealed a high-anion-gap metabolic acidosis, with an initial pH of 6.83. This was consistent with the suspected diagnosis of ethylene glycol poisoning, and the patient was transferred to the intensive care unit for ongoing treatment. Serum ethylene glycol levels were not

ABSTRACT

Ethylene glycol is the active ingredient used in radiator antifreeze. Severe ingestions of ethylene glycol are uncommon in Australia, but if untreated, can result in multiorgan dysfunction, particularly renal failure and cerebral oedema. We report on a patient who consumed a large quantity of ethylene glycol. He was treated with enteral ethanol and went on to make a full recovery, despite an initial moribund state. We briefly review the pathophysiology and current treatment strategies for ethylene glycol intoxication, and discuss issues surrounding enteral versus parenteral ethanol administration.

Crit Care Resusc 2011; 13: 28-32

measured, as samples could not be processed locally, which meant that results would not be available in time to be of any clinical utility.

As the patient was an overseas tourist and travelling alone, there was no available medical history or immediate contacts from which to gather further information. Family members, who were contacted as soon as possible by police, confirmed that the man had no medical history relevant to the current episode.

In the ICU, the patient was commenced on continuous venovenous haemodiafiltration (CVVHDF) and a 10% ethanol infusion (initial loading dose, 2.5 mL/kg; maintenance dose 1-4 mL/kg/h to maintain serum ethanol level 26-39 mmol/L). Sedation was initially maintained with propofol, but switched to morphine and midazolam once the patient was settled in the ICU. Repeat arterial blood gas analysis after 3 hours demonstrated a worsening

Table 1. The patient's vital signs on arrival in the emergency department

Temperature	36.7°C
Heart rate	64 beats/min (regular)
Blood pressure	189/103 mmHg
Respiratory rate	22 breaths/min
Arterial oxygen saturation (SaO ₂)	98% (on 15 L non-rebreather mask)

CASE REPORTS

acidosis (Table 2), so sodium bicarbonate was given. Blood pressure fell to 70 mmHg systolic and a noradrenaline infusion was commenced. By the first evening in the ICU, pharmacy supplies of 100% ethanol for infusion had been depleted, so oral ethanol (in this case, vodka) was given via a nasojunal tube, with the aim of producing similar serum ethanol levels to those obtained via intravenous infusion.

Although the patient's condition stabilised within 24 hours, vasopressors were still required to maintain mean arterial pressures above 70 mmHg. Dialysis was complicated by frequent filter clotting despite adequate vascular access, requiring full systemic anticoagulation. Purulent endotracheal secretions were noted on Day 2 in the ICU and ticarcillin/clavulanic acid 3.1 g 8-hourly was commenced (a sputum sample was later positive for sensitive *Staphylococcus aureus*). A computed tomography (CT) scan of the chest demonstrated bibasal lung consolidation.

CVVHDF was continued (with neutral fluid balance) and biochemical parameters were maintained at normal limits. Feeding was commenced via a nasojunal tube on Day 2. The patient was weaned from sedation without any increase in level of consciousness, so a CT brain scan was performed. This revealed hypodensities in bilateral anterior

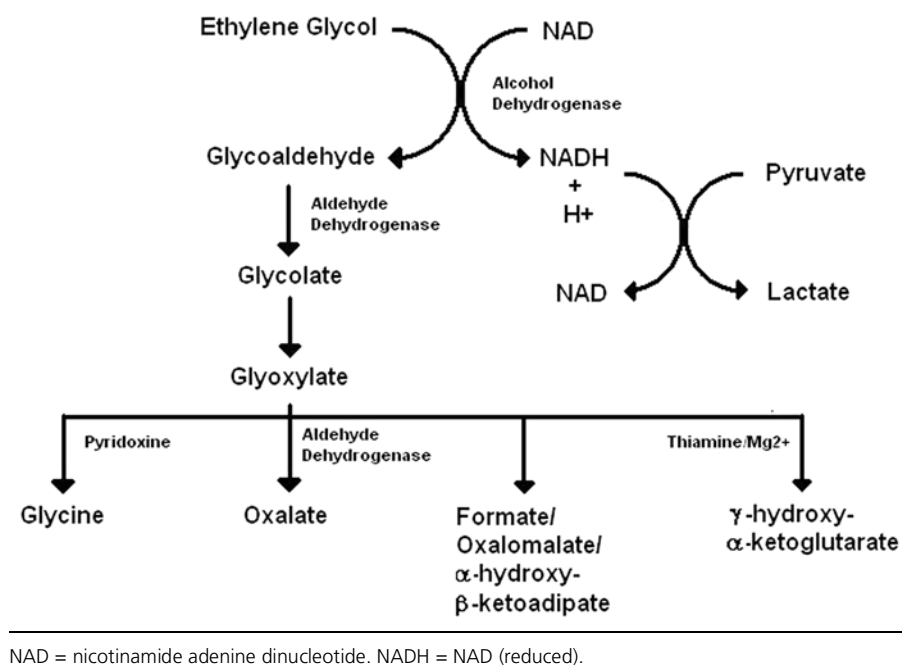
and posterior limbs of the internal capsule and in the region of the external capsule, extending to the medial temporal lobes adjacent to the temporal horns of the lateral ventricles, with sparing of the grey matter.

Generalised oedema was noted on Day 3 with associated anuria, so CVVHDF dosing was modified to obtain a negative fluid balance. Ethanol was ceased on Day 3, as the arterial blood pH had normalised and stabilised. Gradually the patient's condition improved, he was weaned from vasopressors, and was extubated on Day 7. On the following day, CVVHDF was switched to intermittent haemodialysis, which continued for a further 6 days. The patient was then assessed by the mental health team and diagnosed as having a "psychotic fugue", likely as a result of preceding alcohol and drug abuse. On Day 13, he was transferred to the medical ward, where he returned to his previous level of function and health, with only minimal residual renal dysfunction (Table 2). He was discharged from hospital on Day 22. To prevent further recurrences of similar episodes, he was advised by the mental health team to abstain from alcohol and drug-taking and to pursue further counselling as necessary once he returned home. He returned home with his family, and was referred for ongoing renal follow-up by a local specialist.

Table 2. Blood test results during patient's hospital stay

	Presentation	3 hrs	12 hrs	18 hrs	Day 2	Day 3	Day 4	Day 5	Day 6	Day 7	Day 13	Day 22
pH	6.83	6.68	7.21	7.44	7.46	7.37	7.52	7.50	7.50	7.53	—	—
pCO ₂ (mmHg)	20	37	36	27	30	49	42	47	46	43	—	—
pO ₂ (mmHg)	477	380	227	233	156	81	96	70	92	70	—	—
FiO ₂	1.0	0.6	0.4	0.35	0.3	0.5	0.45	0.5	0.55	0.45	—	—
HCO ₃ mmol/L	3	4	14	18	21	28	34	36	36	36	29	25
Base excess (mmol/L)	—	—	-13.0	-4.4	-2.0	2.9	9.9	11.8	11.9	11.9	—	—
Lactate (mmol/L)	—	3.9	5.1	5.4	2.9	5.0	2.9	2.2	2.0	1.5	—	—
Glucose (mmol/L)	16.3	24.6	7.1	5.2	7.6	7.0	7.4	7.7	6.6	6.5	—	—
Anion gap (mmol/L)	31	—	—	17	10	9	8	7	7	5	7	12
Sodium (mmol/L)	142	—	—	141	133	135	136	138	138	135	138	140
Potassium (mmol/L)	6.7	—	—	4.0	3.4	4.7	3.9	3.4	4.6	4.5	4.3	4.7
Urea (mmol/L)	2.4	—	—	3.4	5.7	5.8	6.7	6.5	6.6	9.8	11.4	10.4
Creatinine (μmol/L)	129	—	—	159	245	251	207	191	188	253	333	145
Corrected Ca (mmol/L)	2.14	—	—	2.40	2.50	2.52	2.65	2.66	2.48	2.50	2.26	—
Haemoglobin (g/L)	167	—	—	113	81	72	85	79	79	70	86	109
WCC (× 10 ⁹ /L)	33.1	—	—	26.7	11.9	7.7	12.0	15.9	16.4	14.1	10.7	10.7
Platelets (× 10 ⁹ /L)	408	—	—	196	63	59	71	100	122	151	273	437
INR	1.2	1.9	3.6	1.6	1.1	1.0	1.0	1.0	1.0	1.0	1.1	—
APTT (seconds)	33	>200	>200	>200	34	34	35	40	48	48	35	—
Ethanol (mmol/L)	<3	13	12	32	15	<3	—	—	—	—	—	—

APTT = activated partial thromboplastin time. FiO₂ = fraction of inspired oxygen. INR = international normalised ratio. WCC = white cell count.

Figure 1. Pathway of ethylene glycol metabolism

pathway of ethylene glycol metabolism is shown in Figure 1. Rate-limiting steps occur at ethylene glycol (ADH) and glycolate (lactate dehydrogenase), with resultant accumulation of these compounds. Glycoaldehyde is itself particularly toxic, resulting in cell death via increased oxidative stress, but is likely to have only limited effect in ethylene glycol toxicity, as it is rapidly converted to glycolate.^{2,4,7} Also, glyoxylate itself has limited toxicity, but is readily metabolised to other toxic organic acids (including oxalic acid).^{2,4,7,8} Glycolate is thought to cause most of the organ toxicity in ethylene glycol poisoning via direct cellular toxicity.^{2,4} Progression of ethylene glycol metabolism also promotes lactate production from pyruvate, resulting in increasing acidosis.^{2,7} Binding of oxalic acid to calcium

can reduce the serum calcium level, which may result in coagulopathy, myocyte dysfunction (including cardiac myocytes) and arrhythmias.^{2,7,11}

Treatment of ethylene glycol poisoning, as with all toxicological emergencies, focuses first on airway protection, maintenance of adequate ventilation and circulation, and then on correction of underlying abnormalities.^{2,7,8,14} This centres around preventing formation and the elimination of toxic metabolites, and removal of any unmetabolised ethylene glycol, and is achieved largely through blockade of ADH and renal replacement therapies.^{1,2,5,7,8,11,14,17-19} Correction of any electrolyte and physiological abnormalities is also important, in order to maintain homeostasis as close to normal as possible. Activated charcoal administration is not useful in this context, due to rapid absorption of ethylene glycol via the gastrointestinal mucosa, but may be useful in suspected polypharmacy overdoses.^{2,7,8,11}

ADH may be blocked either directly with the selective inhibitor fomepizole (4-methylpyrazole) or by the use of ethanol (which is preferentially metabolised over other alcohols, saturating the enzyme).^{2,8} Unfortunately, fomepizole is not available for routine use in Australia. Ethanol has been shown to be similarly effective, but it is often difficult to monitor and maintain adequate serum concentrations (particularly during dialysis).^{2,7,8,13} Also the requirement for large doses of intravenous ethanol can create issues of supply, as occurred in our case, necessitating the switch to oral ethanol. This can further increase the difficulty of

Discussion

Our patient was fortunate to have a good outcome after severe ethylene glycol poisoning. Based on the concentration of ethylene glycol in the preparation that the patient ingested (60%), the maximum dose taken was 2.5L (31.25 mL/kg), with the minimum lethal dose in adults being 100 mL (about 1.5 mL/kg) of 95% ethylene glycol.^{2,7,11,14} The patient's arterial blood pH (recorded as 6.68 at its lowest point) is one of the lowest survived, as recorded in the current literature.^{4,6,15-16} Such low pH values, which are often unsurvivable from other causes, appear normal for ethylene glycol poisoning,^{2,6} and although sometimes refractory to bicarbonate infusion, this often appears useful in the correction of acidosis.^{2,4,7-9,11,14} The higher survival rate may be due to the acidosis resulting from high glycolic acid levels after ingestion, rather than from metabolic dysfunction arising from a pathological process,^{2,4,7,8,11,15} although the classical physiological and clinical signs of acidosis are the same.

Ethylene glycol poisoning is characterised by an altered level of consciousness, renal failure, profound metabolic acidosis with an anion gap, and the presence of an osmolar gap.^{1-4,6,8-10} Onset of effects occurs within 4 to 12 hours after ingestion, and can be delayed by coingestion with other alcohols.^{2,7,8,11,17} Toxicity is not a direct result of ethylene glycol itself, but rather its metabolites, particularly glycolate and also oxalic acid, which complexes with serum calcium and deposits within organ tissues.^{1-3,5,6,8,11,17,18} The

CASE REPORTS

maintaining adequate serum levels, due to variable pharmacokinetics.^{2,7,12} Ethanol should be given intravenously as a 10% solution in 5% dextrose, or orally as a roughly 40% solution (there is a decreased need for dilution of ethanol when given via the enteral route). The initial intravenous loading dose should be 7.6 mL/kg, followed by an infusion of 1–2 mL/kg/h.^{2,7} These doses should be quartered for oral administration (due to greater concentration of the oral solution), and may need to be doubled from baseline (for both intravenous and oral administration) during dialysis. These doses should be used as a starting guide, with the aim being maintenance of a serum ethanol level of 26–39 mmol/L.^{2,7,8,11,12} Intravenous administration of ethanol is the preferred route, as absorption is more variable in the gut.^{2,8,11,12}

Enteral ethanol absorption is poorly defined and dependent on multiple factors. Most ethanol absorption occurs in the stomach (20%) and duodenum (80%).²⁰ There is significant first-pass metabolism of enterally delivered ethanol before it is distributed throughout the body.^{2,20,21} This is due mainly to its direct passage via the portal venous system to the liver, but also due to the presence of ADH in the gastric mucosa.^{12,20,21} The level of mucosal ADH is dependent on race (higher in Caucasians), sex (higher in males), and concomitant drug use (reduced with aspirin and H₂ receptor antagonists). Mucosal metabolism of ethanol is more pronounced with delayed gastric emptying, which may be associated with diet (fatty meals), prokinetic drugs (eg, erythromycin) and critical illness. Such an effect is not seen when ethanol is delivered directly to the duodenum or beyond (as was the case in our patient).^{20,22} The first-pass metabolism of ethanol has important ramifications for serum and tissue levels of enterally absorbed ethanol, resulting in lower levels than may be seen with intravenous administration. However, in the case of ethylene glycol poisoning, this difference may not be important, as the goal of ethanol administration is to saturate hepatic ADH. This may occur more rapidly via the enteral route, due to direct portal delivery, although the significance of this difference is likely small because of the low Michaelis constant (K_M) and thus rapid saturation of hepatic ADH via either route of administration.^{20,21}

Other factors that influence the serum level of ethanol, and thus the saturation of hepatic ADH, include its tissue distribution, alternative routes of metabolism, and hepatic blood flow.^{20,21} Ethanol metabolism does not necessarily follow zero-order kinetics as traditionally thought, as it is not solely metabolised by ADH. In chronic ethanol use, induction of cytochrome P450 enzymes allows an alternative metabolic pathway with a much higher K_M , resulting in far more rapid metabolism of ethanol and lower serum levels.^{2,20,21} Furthermore, the distribution of ethanol

throughout the body is related to the amount of body water present, and therefore is a factor of age, sex, and lean body mass.^{20,21} This distribution and its resultant equilibrium with circulating blood volume is not constant, being altered by tissue perfusion, with rapid changes in serum levels seen with alterations in peripheral tissue blood flow.²⁰ Also, blood flow in the splanchnic vessels may be altered due to fasting state, exercise, and critical illness, resulting in altered hepatic perfusion and ethanol metabolism. In summary, delivery of enteral ethanol involves many important considerations by the treating clinician. Ultimately, intravenous ethanol administration is far simpler, but when this is not available, enteral ethanol can be substituted with good effect, as demonstrated in our case. We could find no cases in the literature documenting the use of this treatment modality.

It has been suggested that the use of vitamin supplements may further aid in the conversion of toxic to non-toxic metabolites in ethylene glycol poisoning. Thiamine and magnesium may help in converting glyoxylate to ketones; pyridoxine may help in converting glyoxylate to glycine;^{2,7,8,11} and folate may reduce the conversion of glyoxylate to formate.^{8,11} There are no data on their efficacy in humans for this purpose, but as the risks associated with their use are low, it is not unreasonable they be used.

The modality of renal replacement used is also debated, but in ethylene glycol poisoning, neither continuous nor intermittent haemodialysis seems to have any clear advantage, unless the patient is haemodynamically unstable, in which case continuous haemodialysis appears advantageous.^{2,19} Suggested indications for renal replacement are: serum ethylene glycol level > 4.03 mmol/L; arterial blood pH < 7.25; deteriorating vital signs despite all other treatments; and unexplained anion gap metabolic acidosis with a high index of suspicion for ethylene glycol ingestion.^{2,7,8,11,14} Renal replacement should be continued until all ethylene glycol is removed and the metabolic acidosis is resolved.^{7,9,11,14}

Conclusion

The severity of our patient's acidosis and the treatment of his ethylene glycol poisoning with enteral ethanol are the most notable aspects of this case. It demonstrates that good outcomes may be achieved with simple and readily available therapies. We have also discussed the physiology of ethylene glycol metabolism, current treatment aims and therapies for such poisoning, and the pharmacokinetics and clinical implications of enteral ethanol administration. Although not a common poisoning in Australia, it is readily treatable, with good outcomes. All critical care physicians need to be mindful of ethylene glycol poisoning as a

CASE REPORTS

possible cause of altered level of consciousness and be familiar with its clinical effects and treatment.

Author details

Adam L Holyoak, Registrar in Emergency Medicine and Intensive Care¹

Todd A Fraser, Director of Intensive Care²

Pascal Gelperowicz, Emergency Medicine Specialist³

1 Townsville Hospital, Townsville, QLD, Australia.

2 Mackay Base Hospital, Mackay, QLD, Australia.

3 Austin Hospital, Melbourne, VIC, Australia.

Correspondence: adam_holyoak@health.qld.gov.au

References

- 1 Amathieu R, Merouani M, Borron SW, et al. Prehospital diagnosis of massive ethylene glycol poisoning and use of an early antidote. *Resuscitation* 2006; 70: 285-6.
- 2 Barceloux DG, Krenzelok EP, Olson K, et al. American Academy of Clinical Toxicology practice guidelines on the treatment of ethylene glycol poisoning. *J Toxicol Clin Toxicol* 1999; 37: 537-60.
- 3 Davis DP, Bramwell KJ, Hamilton RS, Williams SR. Ethylene glycol poisoning: case report of a record-high level and a review. *J Emerg Med* 1997; 15: 653-67.
- 4 Fraser AD. Clinical toxicologic implications of ethylene glycol and glycolic acid poisoning. *Ther Drug Monit* 2002; 24: 232-8.
- 5 Krenová M, Pelclová D, Navrátil T, et al. Experiences of the Czech Toxicological Information Centre with ethylene glycol poisoning. *Biomed Pap Med Fac Univ Palacky Olomouc Czech Repub* 2005; 149: 473-5.
- 6 Bey TA, Walter FG, Gibly RL, et al. Survival after ethylene glycol poisoning in a patient with an arterial pH of 6.58. *Vet Hum Toxicol* 2002; 44: 167-8.
- 7 Brent J. Current management of ethylene glycol poisoning. *Drugs* 2001; 61: 979-88.
- 8 Henderson WR, Brubacher J. Methanol and ethylene glycol poisoning: a case study and review of current literature. *CJEM* 2002; 4: 34-40.
- 9 Hylander B, Kjellstrand CM. Prognostic factors and treatment of severe ethylene glycol intoxication. *Intensive Care Med* 1996; 22: 546-52.
- 10 Morgan BW, Ford MD, Follmer R. Ethylene glycol ingestion resulting in brainstem and midbrain dysfunction. *J Toxicol Clin Toxicol* 2000; 38: 445-51.
- 11 Scalley RD, Ferguson DR, Piccaro JC, et al. Treatment of ethylene glycol poisoning. *Am Fam Physician* 2002; 66: 807-12.
- 12 Cobaugh DJ, Gibbs M, Shapiro DE, et al. A comparison of the bioavailabilities of oral and intravenous ethanol in healthy male volunteers. *Acad Emerg Med* 1999; 6: 984-8.
- 13 Green R. The management of severe toxic alcohol ingestions at a tertiary care center after the introduction of fomepizole. *Am J Emerg Med* 2007; 25: 799-803.
- 14 Megarbane B, Borron SW, Baud FJ. Current recommendations for treatment of severe toxic alcohol poisonings. *Intensive Care Med* 2005; 31: 189-95.
- 15 Blakeley KR, Rinner SE, Knochel JP. Survival of ethylene glycol poisoning with profound acidemia. *N Engl J Med* 1993; 328: 515-6.
- 16 Lien D, Mader TJ. Survival from profound alcohol-related lactic acidosis. *J Emerg Med* 1999; 17: 841-6.
- 17 Lovric M, Granic P, Cubrilo-Turek M, et al. Ethylene glycol poisoning. *Forensic Sci Int* 2007; 170: 213-5.
- 18 Chu J, Wang RY, Hill NS. Update in clinical toxicology. *Am J Respir Crit Care Med* 2002; 166: 9-15.
- 19 Goodman JW, Goldfarb DS. The role of continuous renal replacement therapy in the treatment of poisoning. *Semin Dial* 2006; 19: 402-7.
- 20 Norberg A, Jones AW, Hahn RG, et al. Role of variability in explaining ethanol pharmacokinetics. *Clin Pharmacokinet* 2003; 42: 1-31.
- 21 Caballeria J. Current concepts in alcohol metabolism. *Ann Hepatol* 2003; 2: 60-8.
- 22 Deane AM, Fraser RJ, Chapman MJ. Prokinetic drugs for feed intolerance in critical illness: current and potential therapies. *Crit Care Resusc* 2009; 11: 132-43. □