

# Efficacy of the CathRite system to guide bedside placement of peripherally inserted central venous catheters in critically ill patients: a pilot study

Simon J G Hockley, Vida Hamilton, Robert J Young, Marianne J Chapman, James Taylor, Stephanie Creed, Donald P Chorley, Desmond B Williams and Marcus de M Tippet

Critically ill patients in the intensive care unit routinely have a multilumen central venous catheter (CVC) placed as part of management. CVCs facilitate haemodynamic monitoring and infusion of vasoactive medications and hypertonic solutions into the central blood pool. CVCs are commonly inserted via the internal jugular and subclavian veins, and are routinely placed using a “blind” anatomical or ultrasound-assisted technique. Correct positioning is confirmed by routine chest radiography. CVCs have inherent risks of adverse events, including pneumothorax (1.3%–1.5%), neurovascular injury (0.5%–3.0%), bloodstream infections (1.0%–8.6%) and, rarely, cardiac tamponade.<sup>1,2</sup> Specific patient populations are at increased risk of these complications due to their underlying disease (eg, coagulopathy or malignancy).<sup>3</sup> Peripheral vein cannulas are unreliable in critically ill patients, because of oedema and anatomical restrictions, and do not provide long-term multilumen venous access.

Peripherally inserted central cannulas (PICCs) have been suggested as an alternative to standard CVCs, and have significantly less risk and lower infection rates,<sup>4</sup> while fulfilling the requirements for multilumen central venous access and haemodynamic monitoring.<sup>5</sup> Traditional radiological placement of PICCs uses fluoroscopy. Standard blind placement via cephalic or basilic arm veins also requires use of chest radiography to determine the catheter position within the great vessels, and carries a risk of ectopic placement.<sup>6</sup> PICC placement at the bedside without radiological control is unreliable, as demonstrated by Cardella et al,<sup>7</sup> who showed that PICC placement was significantly more successful under fluoroscopic control. However, limitations of fluoroscopy, including patient access and radiation exposure, make this technique unsuitable for catheter placements at the bedside in intensive care settings. Furthermore, other authors<sup>8,9</sup> have shown that blind conventional PICC placements are associated with high rates of clinically evident thrombophlebitis, difficult insertion and malposition on insertion.

The CathRite system (Micronix Pty Ltd, Adelaide, SA) is a novel, portable device that uses inductive sensing technology, and has the potential to overcome many of the

## ABSTRACT

**Objectives:** To assess the efficacy of the CathRite system as a tool to guide clinicians in placement of peripherally inserted central catheters (PICCs) into the superior vena cava (SVC) in critically ill patients.

**Design:** Prospective, randomised, parallel controlled trial.

**Participants and setting:** 38 critically ill patients (mean APACHE II score, 16.6) in a mixed medical and surgical intensive care unit from 2004 to 2006.

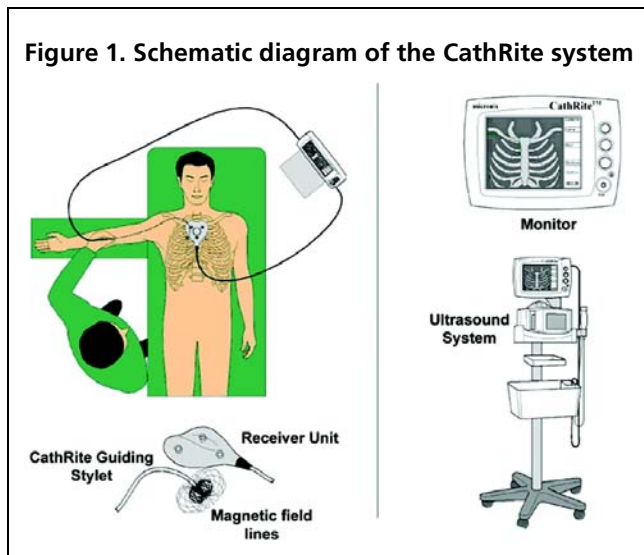
**Interventions:** Participants were randomised to receive PICC placement using either the CathRite system or a standard “blind” technique (control). Peripheral vein cannulation was performed for both groups under ultrasound monitoring, and the PICC was placed using the modified Seldinger technique, with position confirmed using standard chest x-ray.

**Main outcome measures:** Proportion of PICCs guided into the SVC; placement into the lower third of the SVC; and time to complete placement.

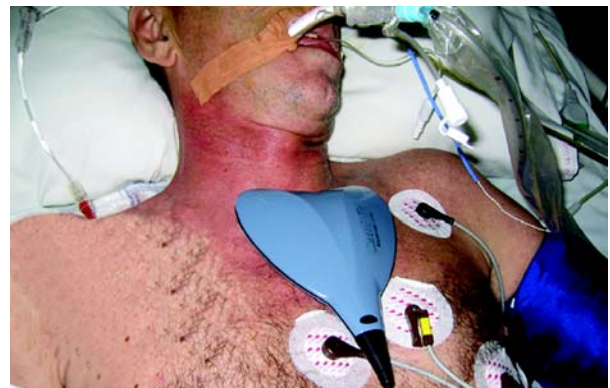**Results:** There was no significant difference between groups in sex distribution or age (CathRite: 12 men, 7 women; mean age  $\pm$  SEM, 61.1  $\pm$  3.4 years; control: 15 men, 4 women; 55.9  $\pm$  4.7 years). The PICC was successfully guided into the SVC in 19 patients (100%) in the CathRite group, compared with 14 (74%) in the control group ( $P < 0.05$ ). Placement of catheters into the lower third of the SVC was achieved in 14 patients (74%) in the CathRite group, compared with eight (42%) in the control group ( $P < 0.05$ ). Time to completion of catheter insertion was 31.4  $\pm$  16.2 minutes in the CathRite group compared with 24.6  $\pm$  14.5 minutes in the control group ( $P = 0.18$ ).

**Conclusions:** The CathRite system enabled placement of PICCs into the SVC from peripheral insertion sites and avoided ectopic placements that occurred with the blind technique.

Crit Care Resusc 2007; 9: 251–255



**Figure 2. Position of the receiver unit**



*The receiver unit is positioned on the anterior chest in relation to the patient's sternum, with its centre located in the midline, and the most superior aspect of the device approximating the sternal notch.*

difficulties associated with PICC placement. CathRite was developed to assist in the real-time guidance of CVCs into the superior vena cava (SVC) at the bedside, without dependence on radiological imaging. This technology has recently been applied in critically ill patients to guide the bedside placement of post-pyloric feeding tubes<sup>10</sup> (COR-TRAK system, Viasys Health Care Medsystems, USA).

PICCs are being used to reduce inpatient admission costs and catheter-related infection rates, as many therapies that were traditionally inpatient have moved to an outpatient setting. Horattas et al<sup>11</sup> found that peripheral central venous access was associated with significant cost savings and fewer severe complications when compared with surgical or radiological approaches. The charge for peripherally inserted central catheters was US\$401 per procedure, compared with \$3870 for radiologically placed peripheral ports and \$3532 to \$4296 for surgically placed catheters.

Our study aimed:

- to assess the efficacy of the CathRite system
  - in guiding placement of PICCs into the SVC at the bedside; and
  - in confirming the placement of PICCs into the lower third of the SVC in critically ill patients; and
- to compare the elapsed time for placement procedures using both the CathRite and standard blind techniques.

## Methods

The study was a prospective, randomised, parallel controlled trial comparing the CathRite system and a standard blind technique for bedside placement of PICCs in critically ill patients.

The study was approved by the Human Research Ethics Committee of the Royal Adelaide Hospital, SA, and run

according to National Health and Medical Research Committee guidelines for the conduct of research on unconscious patients (Declaration of Helsinki). Written informed consent was obtained from the patient or, if the patient was sedated and unable to provide consent, from the next of kin before enrolment in the study.

## Participants and randomisation

Critically ill patients were recruited from a mixed medical and surgical ICU over a 2-year period, 2004–2006. All patients required central venous catheterisation as part of standard medical management. Any patient aged 18 years or over was eligible. Exclusion criteria included the presence of a pacemaker or any other implanted electronic cardiac device, or contraindication to PICC placement because of local sepsis or local venous thrombosis.

Patients were randomly allocated to either the CathRite or the standard blind placement group using STATA version 7 (Stata Statistical Software Release 7, StataCorp, College Station, Tex, USA). Allocated numbers (1–44) were concealed by placing details in sealed opaque envelopes. Allocation took place after consent was obtained and before catheter insertion. All study personnel and participants were blinded to the treatment to which they were assigned before catheter insertion. Patients could re-enter the study when a new PICC was inserted, provided they continued to meet the inclusion and exclusion criteria.

## The CathRite system

The CathRite system comprises a disposable guiding insert (GI), a receiver unit (RU), a monitor and printer. The GI transmits a signal in the form of a low-energy electromagnetic field that is received by the RU, processed and displayed on the monitor (Figure 1). A cable links the RU to the monitor.

The GI is a fine-bore, high-density polyethylene tube housing an inductively coupled transmitter coil at its tip. This is inserted into one of the PICC lumens for the duration of placement. The GI is then attached to the monitor, which incorporates a signal generator. The low-energy electromagnetic field generated by the transmitter coil at the tip of the CathRite GI can be measured by the RU. The RU is positioned on the anterior chest, with its centre located in the midline of the patient's sternum, and the most superior aspect of the device approximating the sternal notch (Figure 2). The RU contains the receiving coils and associated circuitry that measure the signal generated at the tip of the GI. The receiver coils are arranged at the apices of an equilateral triangle. Simultaneous measurements of the transmitter's field intensity are converted to digital data that are represented in the form of three-dimensional coordinates in orthographic space.

An assumption for this application of the technology is that the SVC has a known anatomical relationship to the sternum. Typically, the lower third of the SVC is directly below the attachment of the right third rib on the sternum, a landmark successfully used by Starkhammar et al.<sup>12,13</sup> This point of attachment is about 3 cm below the angle of Louis, a palpable angle formed at the articulation of the manubrium and the sternal blade. It was noted after the second placement with the CathRite system, that the radiographic evidence placed the catheter tip within the region of the right atrium. Based on this knowledge, it was decided to place the catheter tip to the lower border of the second rib; subsequent placement outcomes validated this decision.

The graphic display was designed to represent the passage of the catheter tip as it moves in relation to the sternum, ribs and mid-sagittal line. A graphic representation of a frontal view of the sternal area of the chest cavity and associated ribs is schematically displayed on the monitor (Figure 1). The catheter tip is superimposed on this image as a red sphere that lays down a trace during the catheter placement procedure. Movement of the catheter tip through the vascular anatomy is displayed as a yellow track to create a schematic representation of the catheter as it is being guided into the SVC. The user can switch to a lateral view of placement, where a right lateral aspect of the chest and ribs are depicted during, or at the end of, a procedure to indicate depth. The monitor display of catheter movement against the schematic display representing the sternum and ribs is predicated on the correct positioning of the RU in relation to the third rib. (If the RU is off-centre or skewed, the path laid down during placement is correspondingly off-centre or skewed.)

### Protocol for PICC insertion

All patients were studied in a supine position with head raised at an angle of 5°. Catheter lengths and positions were estimated by a standard procedure of distance measurements from the insertion site, following the anatomical course of the vessel to the suprasternal notch, then onto the inferior border of the second rib. At this point, an external radiopaque marker was placed to which the tip position would be compared on a standard anterior-posterior (AP) chest radiograph. Peripheral vein cannulation was performed with ultrasound guidance (Sonosite iLook ultrasound system, Sonosite Inc, Bothell, Wash, USA). Insertion of the CathRite-guided PICC was via a modified Seldinger technique,<sup>14</sup> which utilised a tearaway sheath-introducer designed by Micronix for use with the Arrow 7 French Tri-lumen catheter.

### Outcome measures

The primary end-points were the proportion of PICCs deemed as having been (i) guided into the SVC; and (ii) placed into the lower third of the SVC when assessed using anterior-posterior (AP) chest radiographs. Successful catheterisation was defined as (i) catheter tip guidance into the SVC, SVC-right atrium, right atrium, right atrium-right ventricle or right ventricle; and (ii) catheter placement within 2 cm of the radiopaque marker on the chest x-ray (inferior border of second rib), which corresponded to the mid to lower third of the SVC. The position of the catheter tip was assessed on standard AP chest radiograph and independently verified for anatomical accuracy by a specialist radiologist, with the radiographs "blinded" before assessment. The time to complete the procedure was defined as the period from skin puncture to final suture insertion.

### Statistical analysis

The trial was designed to enrol 60 patients (30 per group) to detect a difference of 25% between the two groups with 80% power and a type I error rate of 5%. Interim data analysis for the pilot study at 38 patients indicated a statistically significant difference existed, and the study was stopped.

Data are expressed as mean  $\pm$  standard error of the mean (SEM). Differences in insertion time between the two techniques were compared using Student's unpaired *t* test. Time taken for repeat x-rays for the control group was not measured. An association between the type of treatment and placement in the SVC was assessed using Fisher's exact test. The proportion of catheters placed into the lower third of the SVC were compared between the two groups using  $\chi^2$  tests. A *P* value  $<0.05$  was considered statistically significant.

**Table 1. Characteristics of participants by treatment group (mean ± SEM)\***

	CathRite system (n = 19)	Blind placement (n = 19)
Age (years)	61.1 ± 3.4	55.9 ± 4.7
Sex (M:F)	12:7	15:4
Weight (kg)	80.1 ± 6.5	84.6 ± 5.4
Height (cm)	168.4 ± 2.3	176.5 ± 1.7
Body mass index (kg/m <sup>2</sup> )	28.6 ± 2.6	27.6 ± 2.3
APACHE II score	16.6 ± 1.4	16.6 ± 1.6

\*Unless otherwise indicated.

**Table 2. Comparison of outcomes between the CathRite and blind placement groups (number of patients)**

	CathRite system (n = 19)	Blind placement (n = 19)
PICC guidance into the SVC	19 (100%)*	14 (74%)
Placement in the lower third of the SVC	14 (74%)*	8 (42%)

\*P < 0.05.

PICC = peripherally inserted central catheter. SVC = superior vena cava.

## Results

Forty-four patients were enrolled in the study, with 22 allocated to the Cath Rite group and 22 to the control group. Of those enrolled, six were excluded from the analysis (three in each group), because of failed cannulation of the arm vein (five patients) and non-diagnostic chest radiograph (one patient) (the tip could not be visualised as the patient was very obese, causing beam scatter and a "flat" image). There were no significant differences in age, sex distribution, weight or APACHE II score between the two groups. Although a difference in height was noted, no difference in body mass index was found (Table 1). Adverse events recorded during the study were an infected subclavian vein thrombosis, which was successfully treated (one patient), and infection of the insertion site (non-systemic) (one patient).

## Outcomes

**PICC guidance and placement in the SVC:** PICCs were radiographically assessed as being placed into the SVC in all 19 patients using the CathRite system, compared with 14 of the 19 patients in the control group (Table 2).

**Placement in the lower third of the SVC:** PICCs were radiographically assessed as being placed into the lower third of the SVC in 14 patients using the CathRite system (74%), compared with eight patients in the blind placement group (42%) (Table 2).

**Time to completion of catheter insertion:** The number of patients was too small to determine any significant differences in time between the two techniques (CathRite system, 31.4 ± 16.2 minutes; versus blind placement, 24.6 ± 14.5 minutes; P = 0.18).

## Discussion

Central venous catheters are essential for the care of many critically ill patients in all age groups. In the United States, over 5 million CVCs are inserted by medical practitioners annually.<sup>2</sup> PICCs can be placed in critically ill patients to provide multiport venous access. Recent studies<sup>4,5</sup> have shown lower rates of morbidity in terms of iatrogenic injury and catheter-related sepsis for PICCs, when compared with conventionally placed CVCs.

Our study substantiated the capacity of the CathRite system to enable us to consistently guide placements to the region radiologically assessed as the SVC, and to avoid placements into ectopic sites. When the catheter tip was noted to be veering from the preferred path, it was possible to redirect it toward the SVC, by interpreting the information supplied by the monitor display, eliminating the need for a second x-ray in the CathRite group. Five of the 19 PICCs placed blind (26%) were deemed ectopic on x-ray (placed to a non-central location within the venous system — ie, right internal jugular, brachiocephalic or subclavian vein), necessitating repositioning and additional x-rays.<sup>15</sup> These additional times were not measured.

Discussions about the ideal terminal position for CVCs suggest that all tip positions have inherent risks, and that there is no ideal tip location devoid of risks.<sup>16</sup> Many users prefer tip placement into the lower third of the SVC. We found much higher rates of placement into this location in the CathRite group (74%) compared with the blind-placement group (42%).

The US Food and Drug Administration<sup>17</sup> and the National Association of Vascular Access Networks<sup>18</sup> state that catheters should not be placed within, and should not enter, the heart, and must be located above the SVC–right atrial (RA) junction to reduce the risk of arrhythmias, perforation and tamponade. Localisation of the inferior border of the SVC at the SVC–RA junction using radiological landmarks is imprecise on standard chest x-ray. The right main bronchial angle and carina are traditional anatomical markers that are evident on chest radiographs of the mid to lower portions of the SVC.<sup>19</sup> Evaluation of the anatomy of the SVC using

multiplanar magnetic resonance imaging indicates that the position of the SVC–RA junction is up to 2.9 cm caudal to the right main bronchial angle. The lower third of the SVC was chosen for tip placement in this study.<sup>16</sup>

The variables that affect consistent placement into the lower third of the SVC are anatomical variability of patients and sensitivity of the technology to portray catheter tip placement in relation to surface anatomical landmarks.

A third set of variables relates to the portrayal of catheter-tip placement into the SVC using radiological landmarks, as this is currently the standard reference for estimating tip placement. Radiological methods have their own limitations, and neither these, nor factors affecting reproducibility of radiological verification, are discussed here.

Continuous real-time display of catheter movement can be achieved by fluoroscopy. However, fluoroscopy is confined to two-dimensional views, is potentially hazardous to both staff and patients, and is difficult logistically in critically ill patients. CathRite provides multiple views and real-time display without radiation exposure, overcoming some of the problems inherent in radiology as an imaging technique. CathRite therefore has the potential to assist in the real-time guidance of PICCs into the SVC at the bedside, reducing dependence on chest radiography. Inductive sensing technology has the potential to improve patient management by enabling more timely intervention.

## Conclusions

This study demonstrated that the CathRite system was efficacious when compared with a standard technique of PICC placement. The CathRite system allowed guidance of PICCs into regions radiographically assessed as the SVC in all participants.

It is likely that a more detailed understanding of the range of anatomical variations in the topography of the SVC in relation to surface anatomy will enable PICC guidance to specific locations within the SVC using the CathRite system. Future adaptations of the device may also include guidance of CVCs from the jugular and subclavian approaches.

## Acknowledgements

We would like to thank Ms Justine Rivett and Mr Jason Edwards (Intensive Care Unit, Royal Adelaide Hospital), and Ms Laura Bryant (Department of Gastroenterology, Royal Adelaide Hospital). We also thank Mr Thomas Sullivan (University of Adelaide) for statistical guidance. This study was supported by a research grant from Micronix Pty Ltd, Adelaide, SA.

## Author details

Simon JG Hockley, Registrar<sup>1</sup>  
Vida Hamilton, Chief Registrar<sup>1</sup>

Robert J Young, Staff Specialist<sup>1</sup>

Marianne J Chapman, Staff Specialist<sup>1</sup>

James Taylor, Director of Radiology<sup>2</sup>

Stephanie Creed, Clinical Research Manager<sup>1</sup>

Donald P Chorley, Director Applications<sup>3</sup>

Desmond B Williams, Senior Lecturer<sup>4</sup>

Marcus de M Tippet, Regulatory Consultant<sup>3</sup>

<sup>1</sup> Department of Anaesthesia and Intensive Care Unit, Royal Adelaide Hospital, Adelaide, SA.

<sup>2</sup> Department of Radiology, Royal Adelaide Hospital, Adelaide, SA.

<sup>3</sup> Micronix Pty Ltd, Adelaide, SA.

<sup>4</sup> Sansom Institute, School of Pharmacy and Medical Sciences, University of South Australia, Adelaide, SA.

**Correspondence:** robert.young@health.sa.gov.au

## References

- Ruesch S, Walder B, Tramer MR. Complications of central venous catheters. Internal jugular versus subclavian access — a systematic review. *Crit Care Med* 2002; 30: 454-60.
- McGee DC, Gould MK. Preventing complications of central venous catheterization. *N Engl J Med* 2003; 348: 1123-33.
- Cheong K, Perry D, Karapetis C, Koczwara B. High rate of complications associated with peripherally inserted central venous catheters in patients with solid tumours. *Intern Med J* 2004; 34: 234-8.
- Royer T, Lang E, Neuzil K, et al. Peripherally inserted central catheter (PICC) bloodstream infection surveillance rates in medical intensive care, medical — surgical wards, extended care, and outpatients. *Am J Infect Control* 2005; 33: e15-6.
- Griffiths VR, Philpot P. Peripherally inserted central catheters (PICCs): do they have a role in the care of the critically ill patient? *Intensive Crit Care Nurs* 2002; 18: 37-47.
- Timberlake CM. Central venous access — a problem with a peripheral approach. *Anaesthesia* 1999; 54: 513.
- Cardella JF, Fox PS, Lawler JB. Interventional radiologic placement of peripherally inserted central catheters. *J Vasc Interv Radiol* 1993; 4: 653-60.
- Cowl CT, Weinstock JV, Al-Jurf A, et al. Complications and cost associated with parenteral nutrition delivered to hospitalized patients through either subclavian or peripherally-inserted central catheters. *Clin Nutr* 2000; 19: 237-43.
- Grove JR, Pevec WC. Venous thrombosis related to peripherally inserted central catheters. *J Vasc Interv Radiol* 2000; 11: 837-40.
- Young RJ, Chapman MJ, Fraser R, et al. A novel technique for post-pyloric feeding tube placement in critically ill patients: a pilot study. *Anaesth Intensive Care* 2005; 33: 229-34.
- Horattas MC, Trupiano J, Hopkins S, et al. Changing concepts in long-term central venous access: catheter selection and cost savings. *Am J Infect Control* 2001; 29: 32-40.
- Starkhammar H, Bengtsson M, Kay DA, et al. Central venous catheter placement using electromagnetic position sensing: a clinical evaluation. *Biomed Instrum Technol* 1996; 30: 164-70.
- Starkhammar H, Bengtsson M, Kay DA, et al. CathFinder catheter tracking system: a new device for positioning of central venous catheters. Early experience from implantation of brachial portal systems. *Acta Anaesth Scand* 1990; 34: 296-300.
- Higgs ZC, Macafee DA, Braithwaite BD, et al. The Seldinger technique: 50 years on. *Lancet* 2005; 366: 1407-9.
- LaRue GD. Improving central placement rates of peripherally inserted catheters. *J Intraven Nurs* 1995; 18: 24-7.
- Vesely TM. Central venous catheter tip position: a continuing controversy. *J Vasc Interv Radiol* 2003; 14: 527-34.
- Food and Drug Administration. Precautions necessary with central venous catheters. FDA Task Force. *FDA Drug Bull* 1989; 15-6.
- National Association of Vascular Access Networks. NAVAN Position Statement. *J Vasc Access Devices* 1998; 3: 8-10.
- Fletcher SJ, Bodenham AR. Safe placement of central venous catheters: where should the tip of the catheter lie? *Br J Anaesth* 2000; 85: 188-91. □